

Pediatric Difficult Airway Management: New Modalities

Paul Stricker, MD
Children's Hospital of Philadelphia
University of Pennsylvania School of Medicine



Goals

- Review pediatric anatomy and physiology as they relate to airway management
- Discuss current devices available for use in children
- Present an approach to difficult airway management in infants and children
- Present two useful techniques
- Present relevant literature

Farcus

by David Waisglass
Gordon Coulthart



**“What conflict of interest?!
I work here in my spare time.”**

What makes the
pediatric difficult airway
different?

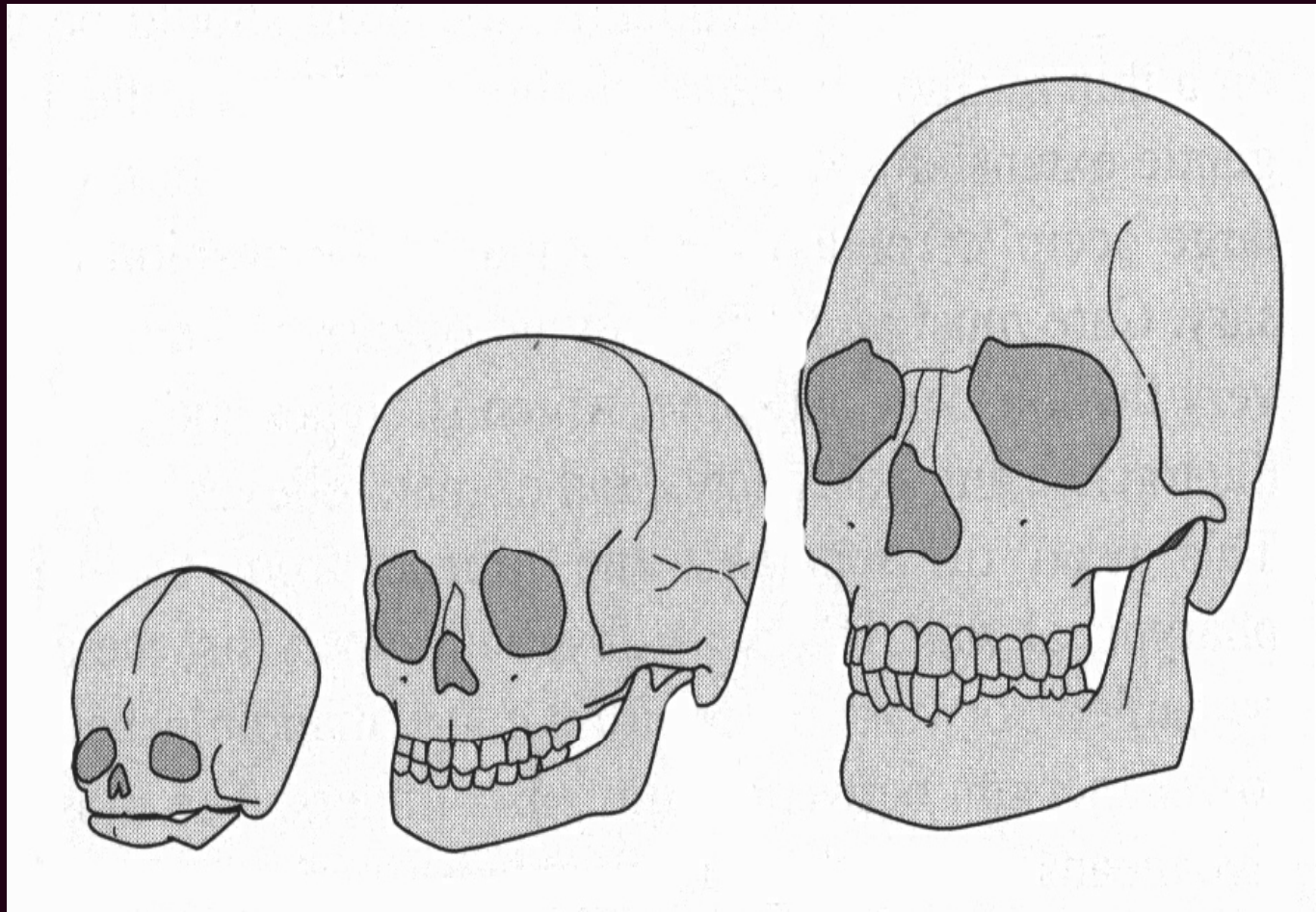


Infant physiology: *Tempus fugit...*

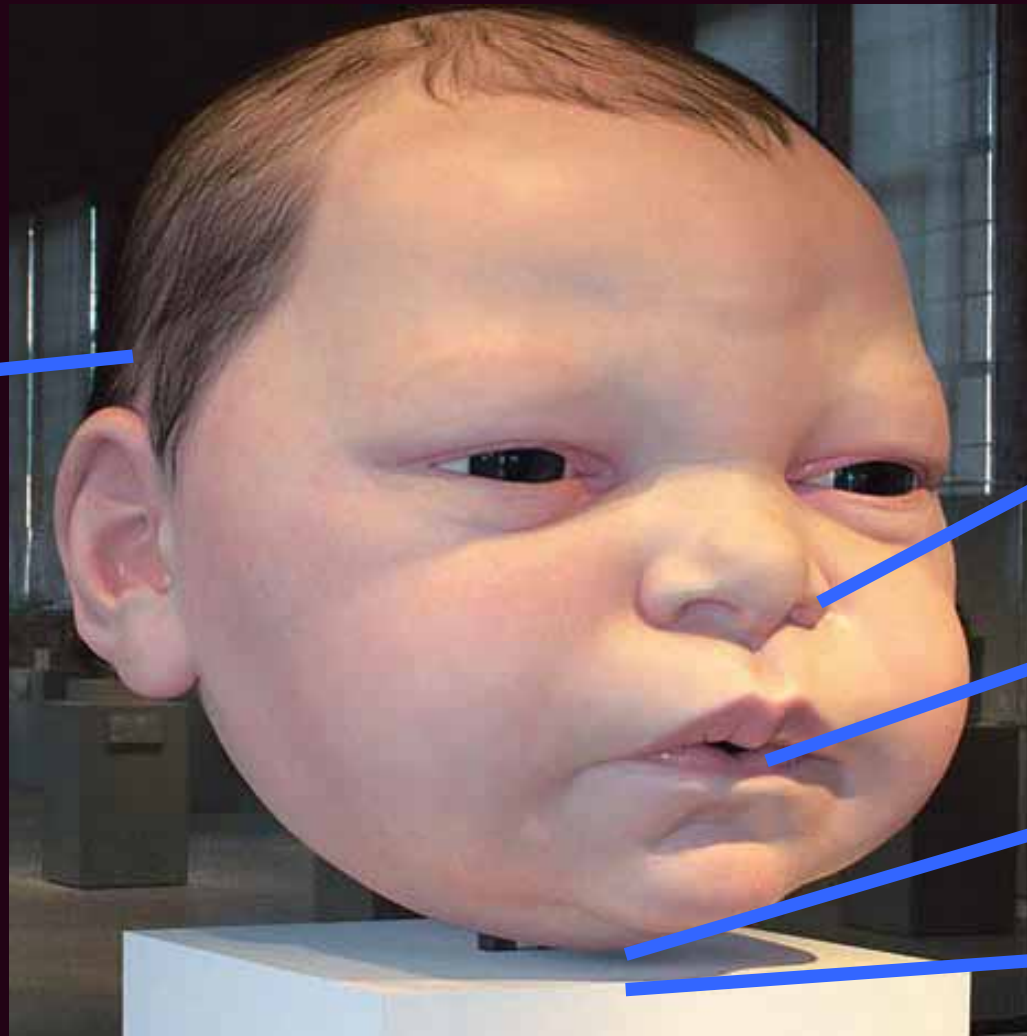
- High metabolic rate:
7-9 mL O₂/kg/min vs.
3 mL O₂/kg/min in
adult
- Reduced FRC
- Elevated closing
volume
- Rapid oxyhemoglobin
desaturation when
apneic



The Pediatric Airway is Different...



The Pediatric Airway is Different...



Large occiput

Narrow nares

Large tongue


High larynx

Narrow cricoid

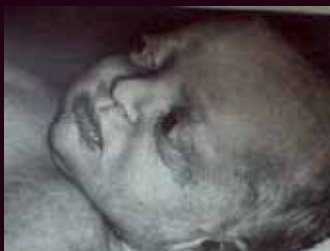
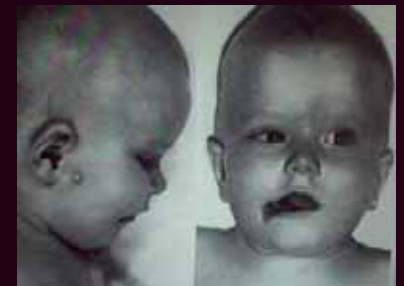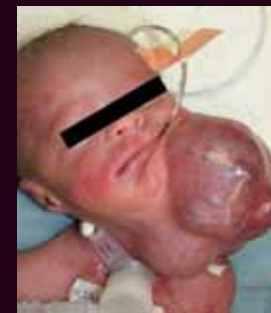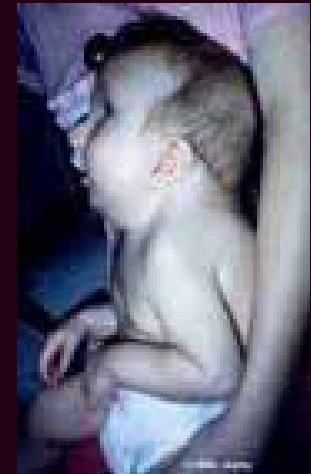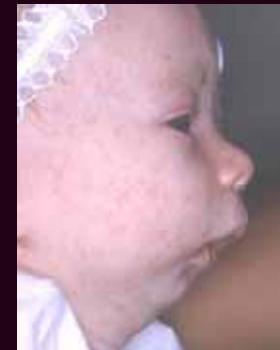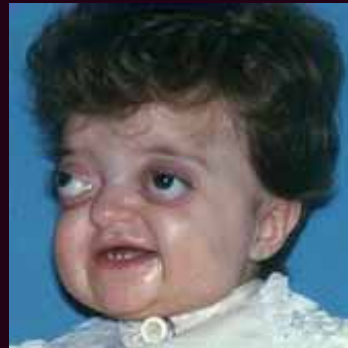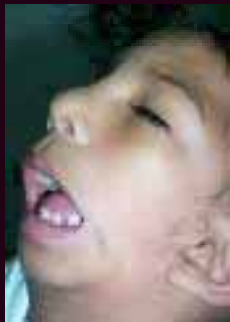Ron Mueck's Baby Head

Pediatric psychology, the word “NO!” and airway management...

- Awake/sedated approaches to intubation used in adult difficult airways are more problematic
- For pediatric patients, anesthetized intubation remains most common
- Weight-based limitations in local anesthetics for airway anesthesia
- Despite all of the differences, there is no ASA difficult pediatric



The Difficult Pediatric Airway



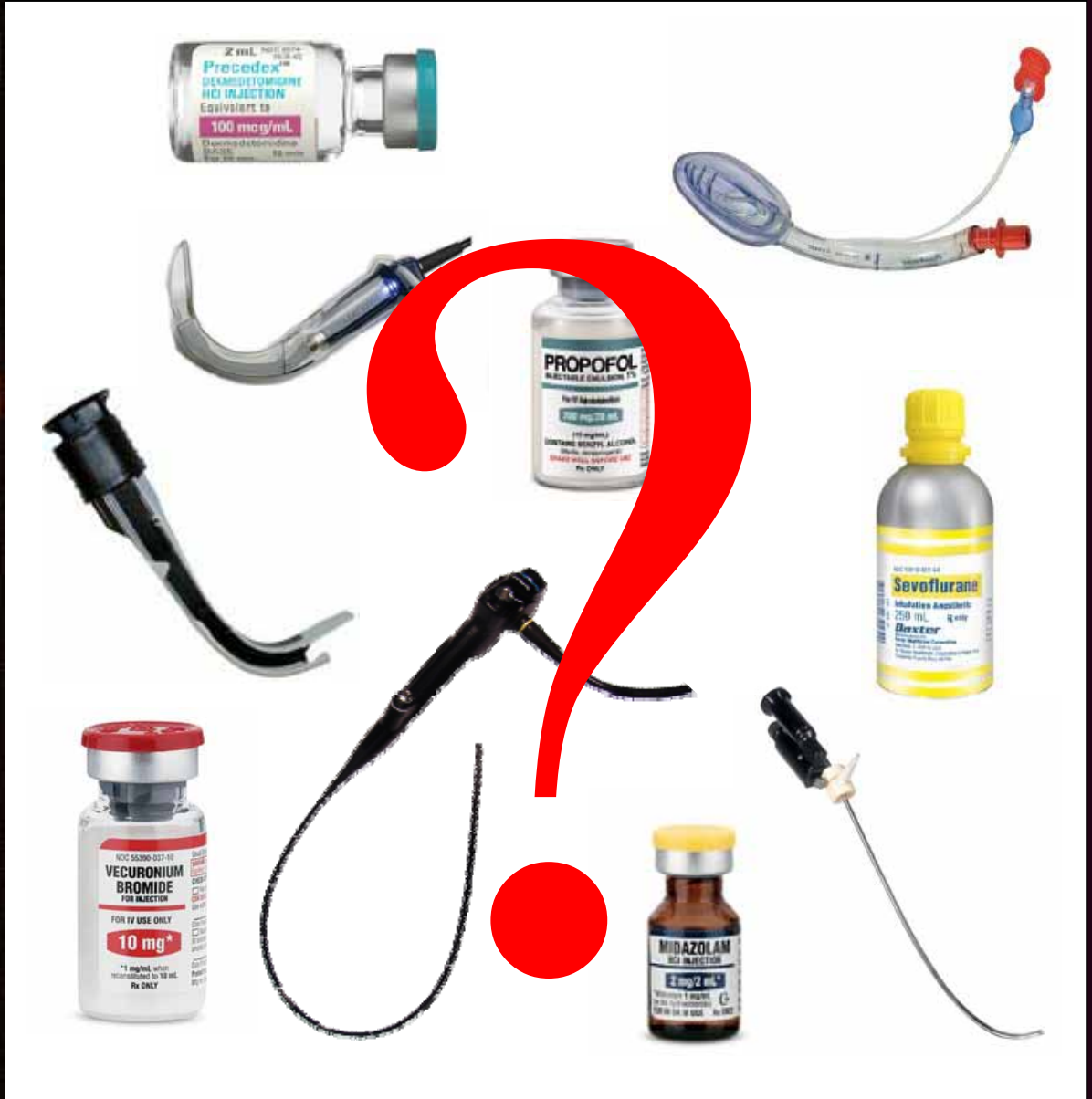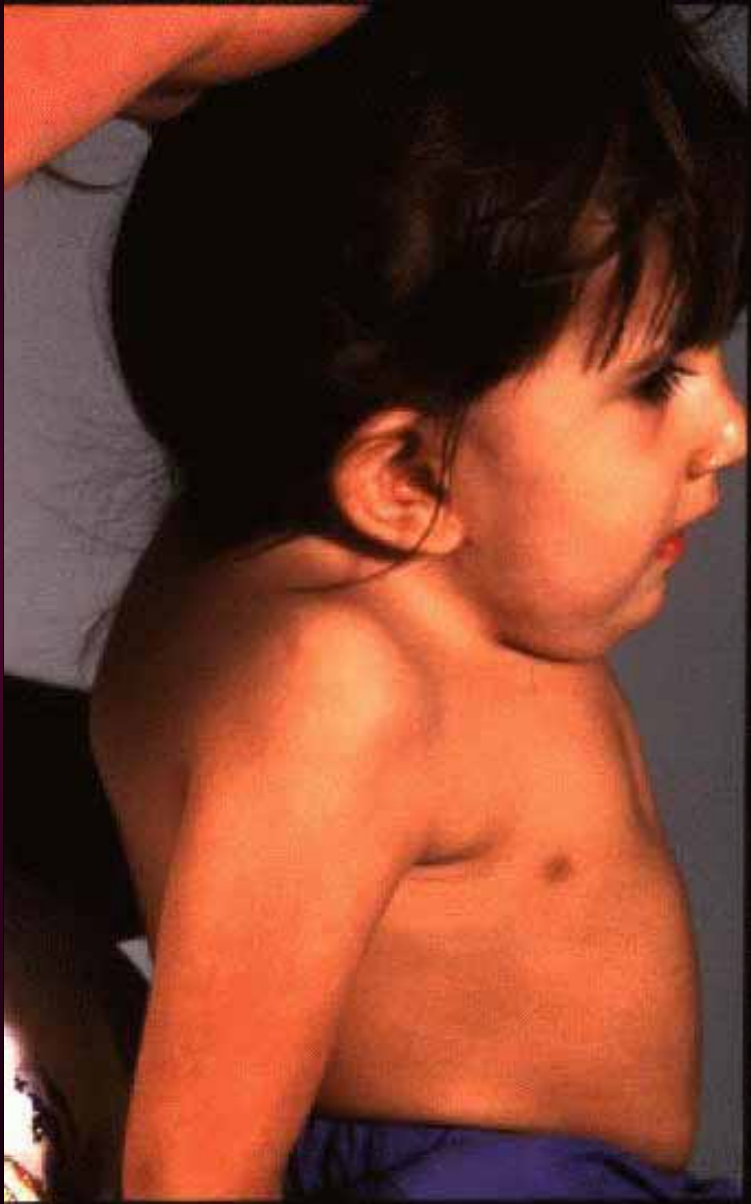What is a Difficult Airway?

“The clinical situation in which a conventionally trained anesthesiologist experiences difficulty with face mask ventilation of the upper airway, difficulty with tracheal intubation, or both.”

-Suggested definition from
2003 ASA Practice Guidelines

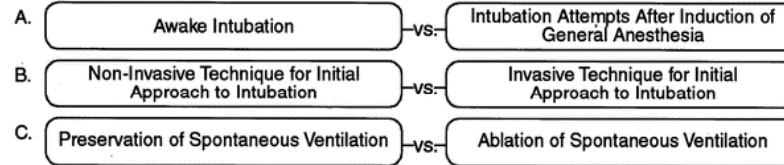
Diseases and Syndromes Associated with the Difficult Pediatric Airway

Trisomy 18, Tracheal agenesis, Laryngeal atresia, Congenital fusion of the jaw, LTE cleft, Laryngeal web, Congenital laryngeal stenosis, Ankylosis of the TMJ, Cystic hygroma, Goldenhar's, Robin sequence, Treacher-Collin's, Hallerman-Streiff, Hemifacial microsomia, Cleft palate, Nager's, Down's, Cockayne's, Cri-du-chat, Russel-Silver, Trismus, Dystrophic epidermolysis bullosa, Klippel-Feil, Microstomia, Epiglottitis, Lingual tonsillitis, Abscess, Rheumatoid disease, Ludwig's angina, C-spine injury, Laryngeal trauma, Burns, Hematomas, Achondroplasia, Arthrogryposis multiplex congenita, Beckwith-Wiedemann, Fibrodysplasia ossificans progressiva, Lipoid proteinosis, Lipodosis, Mucopolysaccharidosis, Hurler, Hunter, Scheie, Sanfilippo, Morquio, Maroteaux-Lamy, Freeman-Sheldon, Muscle-eye-brain disease, Angio edema, Turner, Noonan, Thalassemia major, Stevens-Johnson, Smith-Lemli-Optiz, Scleroderma, Rubinstein-Taybi, Pompe disease, Laryngotracheal papillomatosis, Marfan, Crouzon, Apert, Cornelia de Lange, Cherubism.....

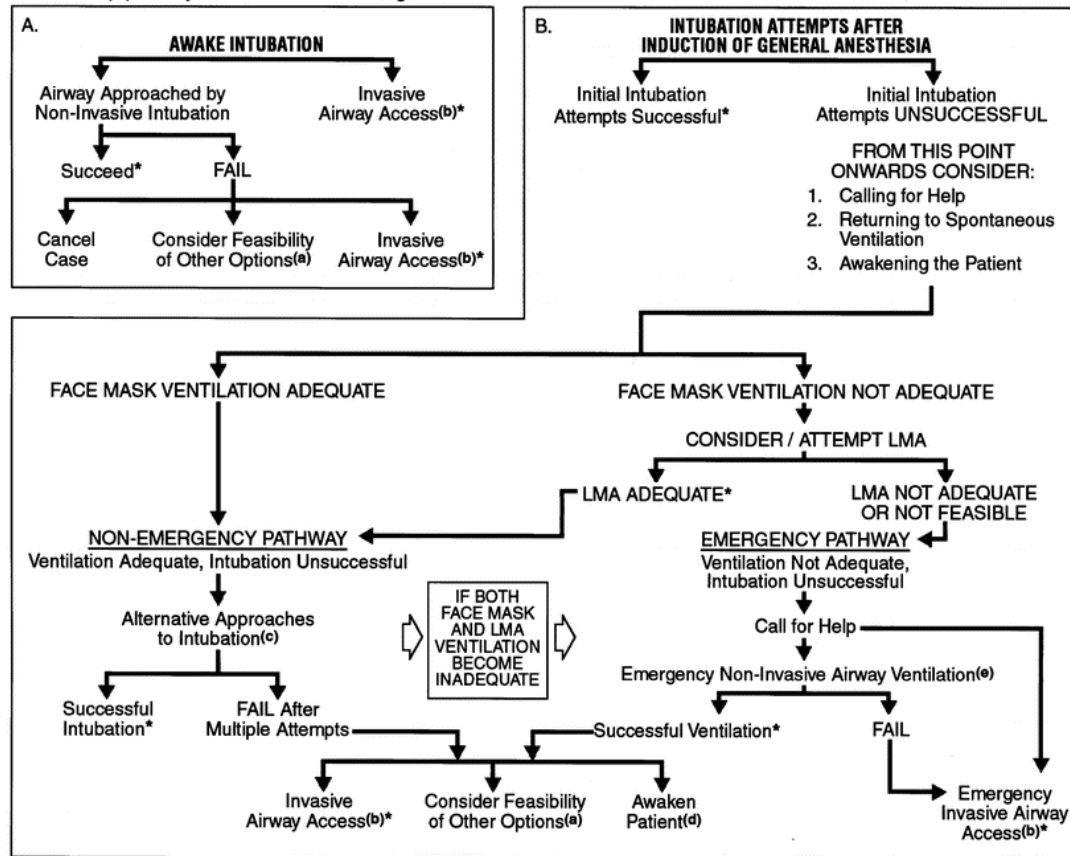


DIFFICULT AIRWAY ALGORITHM

1. Assess the likelihood and clinical impact of basic management problems:
 - A. Difficult Ventilation
 - B. Difficult Intubation
 - C. Difficulty with Patient Cooperation or Consent
 - D. Difficult Tracheostomy
2. Actively pursue opportunities to deliver supplemental oxygen throughout the process of difficult airway management
3. Consider the relative merits and feasibility of basic management choices:



4. Develop primary and alternative strategies:



* Confirm ventilation, tracheal intubation, or LMA placement with exhaled CO₂

a. Other options include (but are not limited to): surgery utilizing face mask or LMA anesthesia, local anesthesia infiltration or regional nerve blockade. Pursuit of these options usually implies that mask ventilation will not be problematic. Therefore, these options may be of limited value if this step in the algorithm has been reached via the Emergency Pathway.

b. Invasive airway access includes surgical or percutaneous tracheostomy or cricothyrotomy.

c. Alternative non-invasive approaches to difficult intubation include (but are not limited to): use of different laryngoscope blades, LMA as an intubation conduit (with or without fiberoptic guidance), fiberoptic intubation, intubating stylet or tube changer, light wand, retrograde intubation, and blind oral or nasal intubation.

d. Consider re-preparation of the patient for awake intubation or canceling surgery.


e. Options for emergency non-invasive airway ventilation include (but are not limited to): rigid bronchoscope, esophageal-tracheal combitube ventilation, or transtracheal jet ventilation.



“There is an uneasy combination of science and art in airway management, and much of our practice is based on anecdote and opinion.”

-Ian Calder, *Anesthesiology*
2007;107:171

Preparation → Success

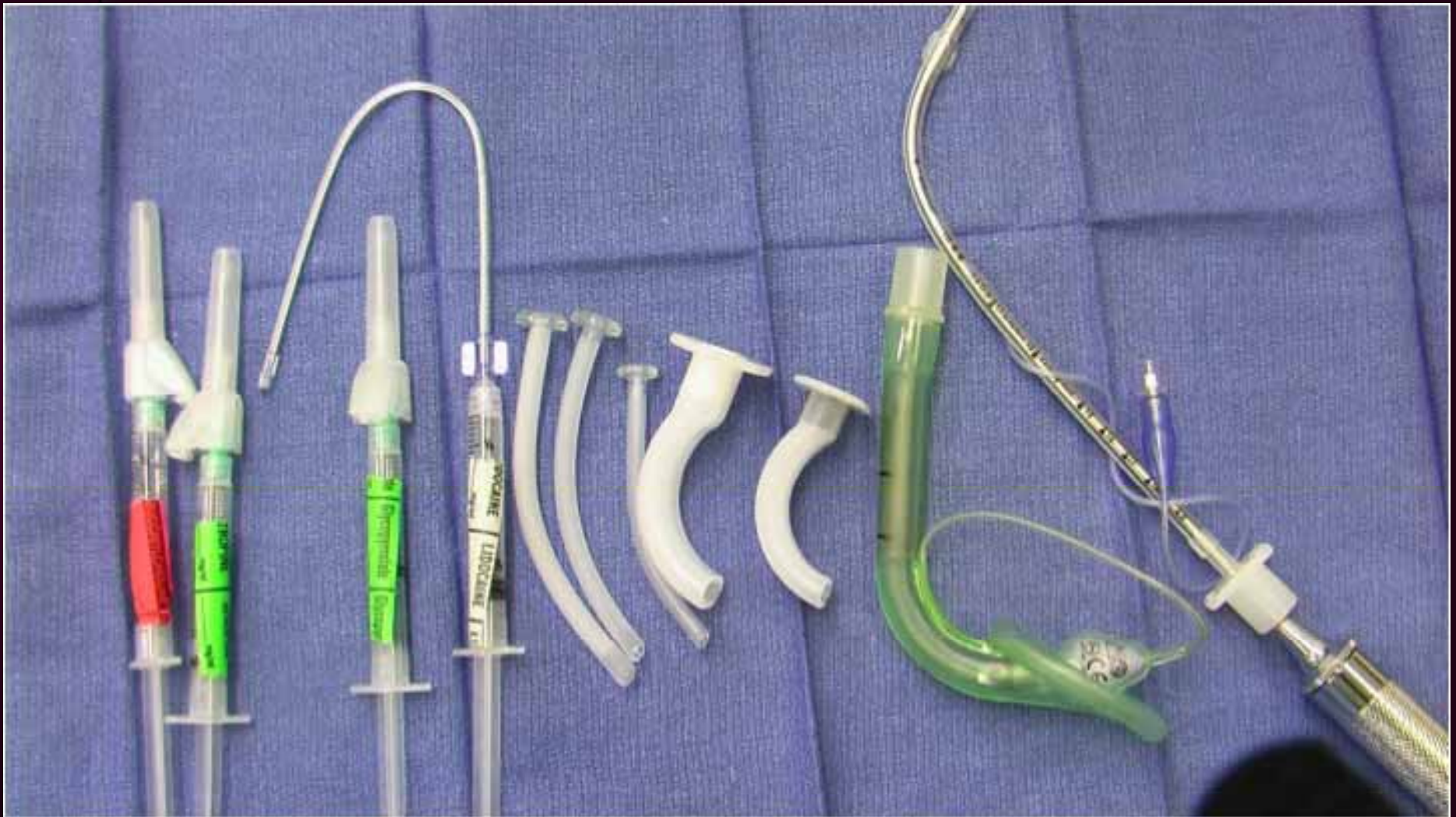

Preoperative Preparation

- Preop airway exam
- *External* anatomy in younger children
 - Micrognathia
 - High arched palate
 - Mouth opening
 - Cervical mobility
 - Dentition
- Develop Plans A, B, and C
- Equipment preparation



Preoperative Preparation for the Anticipated Difficult Airway



Will ventilation by
facemask be
difficult?

What is Difficult Mask Ventilation?

Han scale:

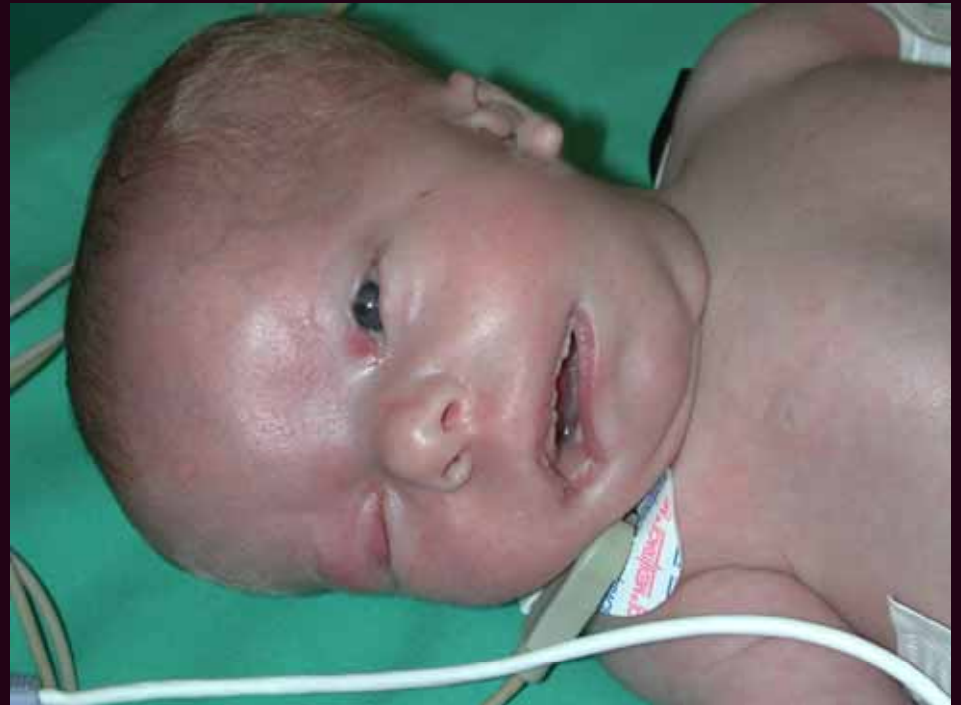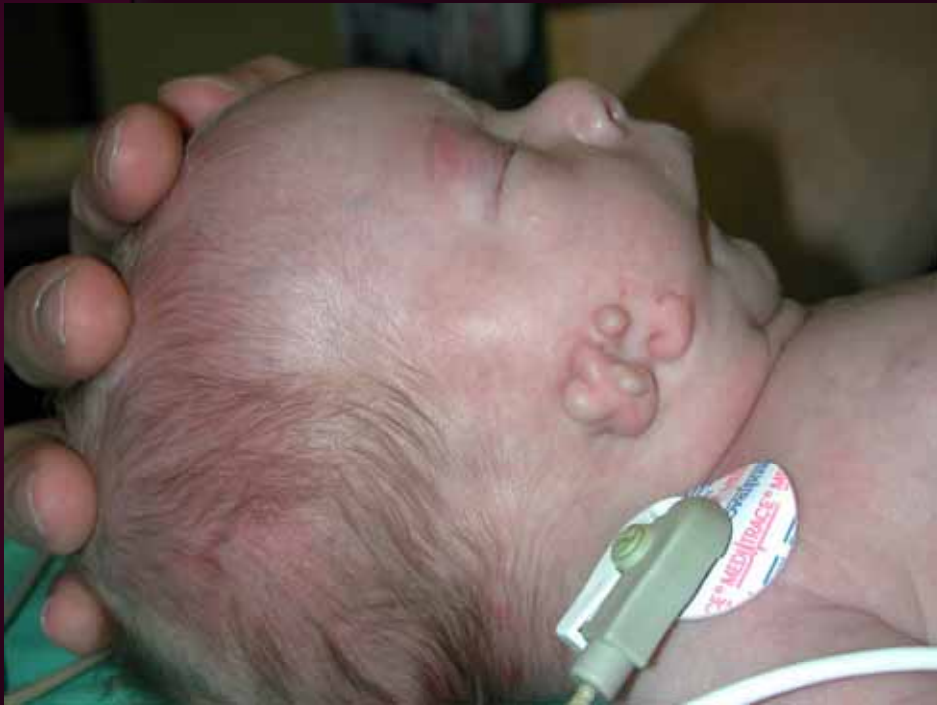Grade	Description
1	Ventilated by mask
2	Ventilated by mask with oral airway/adjuvant with or without muscle relaxant
3	Difficult ventilation (inadequate, unstable, or requiring two providers) with or without muscle relaxant
4	Unable to mask ventilate with or without muscle relaxant

Difficult Mask Ventilation

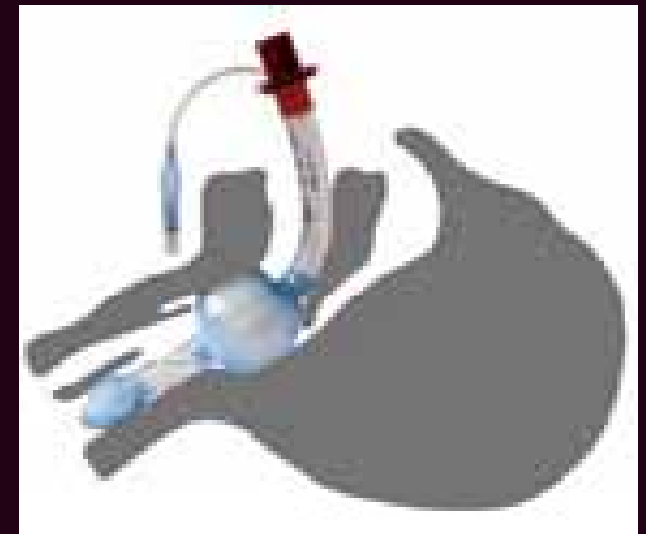
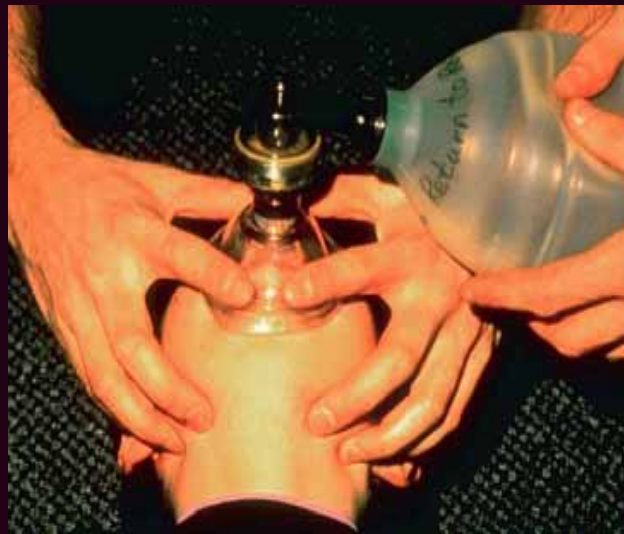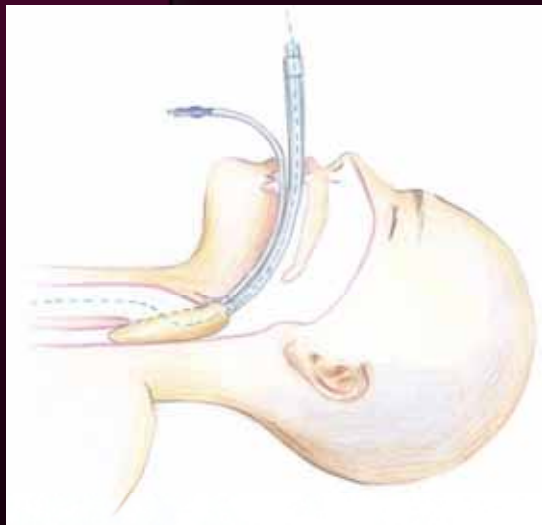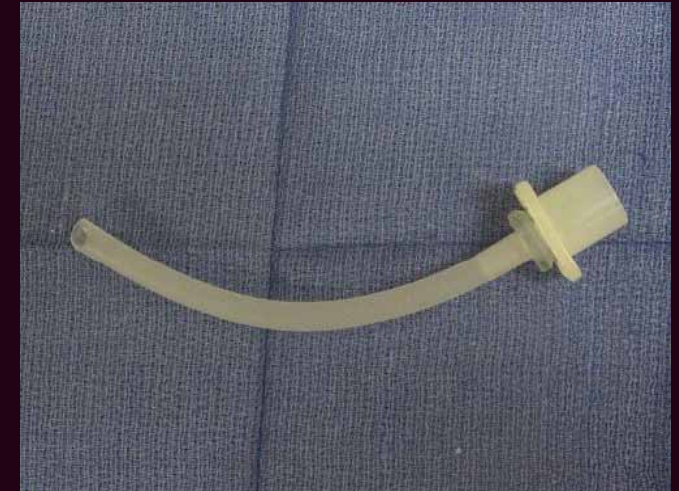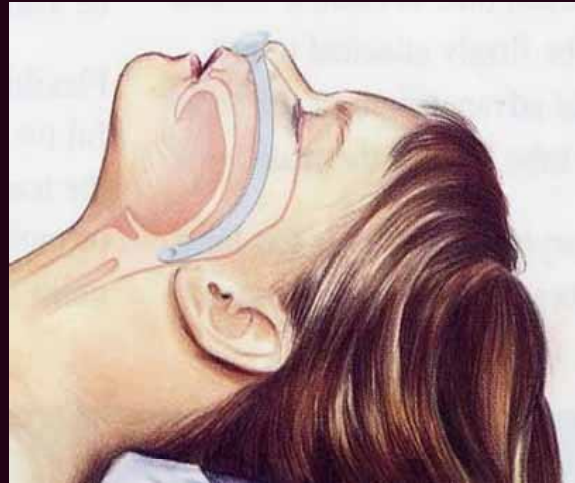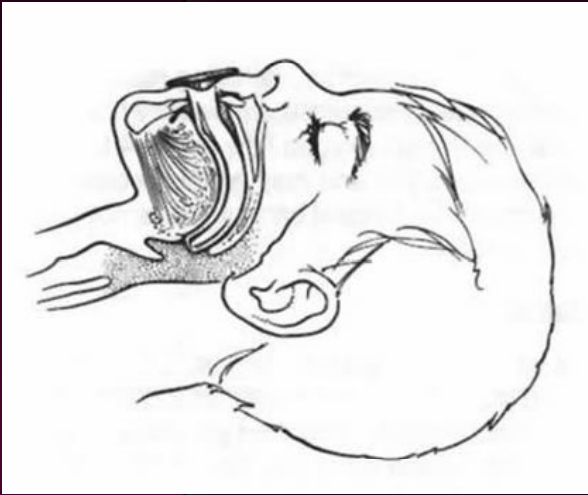- Incidence of DMV in adults:
 - 1.4% (Kheterpal *et al. Anesthesiology* 2006: 22,660 anesthetics)
 - 2.2% (Kheterpal *et al. Anesthesiology* 2009: 50,000 anesthetics)
 - 5% (Langeron *et al. Anesthesiology* 2000: 1,502 anesthetics)
- Incidence of DMV in pediatrics:
 - 2.1% in non-obese children
(Tait *et al. Anesthesiology* 2008: 2,025 anesthetics)



Will I be able to ventilate?
I think so but maybe not...



Ventilation Adjuncts: 2010



Difficult Ventilation?

Yes

No

Awake/sedated
approach feasible?

Intubation attempts under
general anesthesia

Yes

No


Awake/ sedated
intubation:

- Nasal FOI
- Optical stylet
- Oral FOI

Intubation
attempts under
general
anesthesia

ASA 2003 Practice Guidelines

“Airway management in the uncooperative or pediatric patient may require an approach (e.g. intubation attempts after induction of general anesthesia) that might not be regarded as the primary approach in a cooperative patient.”



Difficult Ventilation?

Yes

No

Awake/sedated approach feasible?

Yes

No

Awake/ sedated intubation:

- Nasal FOI
- Optical stylet
- Oral FOI

Intubation attempts under general anesthesia

Intubation attempts under general anesthesia

Mouth opening adequate for oral airway or LMA insertion?

Yes

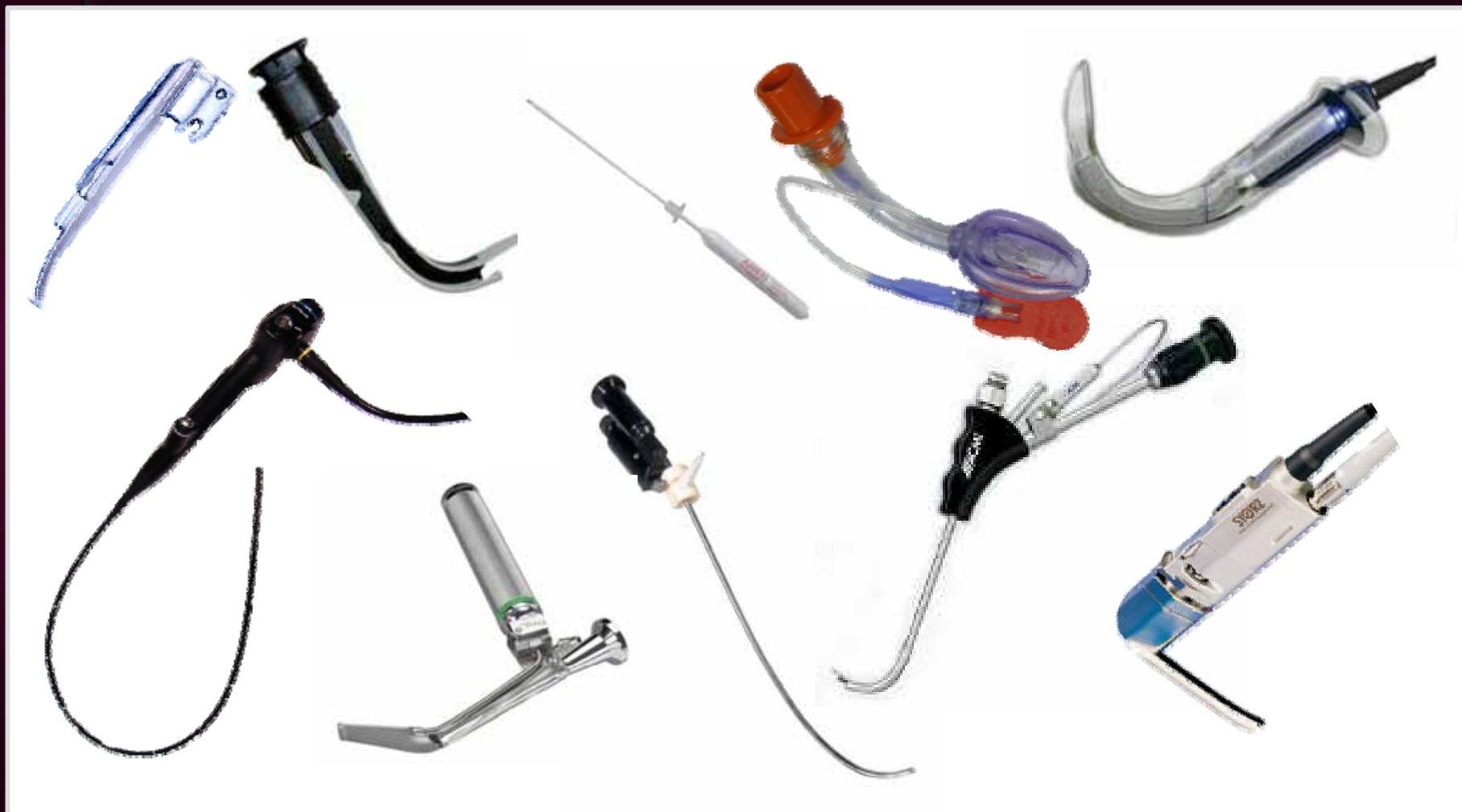No

- Nasal FOI
- Oral FOI
- Intubation through LM
- Video laryngoscopy
- Optical stylet
- Lighted stylet
- Direct laryngoscopy

- Nasal FOI

Consider awake/sedated approach to intubation if feasible

Tracheal Intubation Tools: 2010



**A tool is not a
plan!!**

Creating the Plan



DIFFICULT AIRWAY ALGORITHM

1. Assess the likelihood and clinical impact of basic management problems:
 - A. Difficult Ventilation
 - B. Difficult Intubation
 - C. Difficulty with Patient Cooperation or Consent
 - D. Difficult Tracheostomy
2. Actively pursue opportunities to deliver supplemental oxygen throughout the process of difficult airway management
3. Consider the relative merits and feasibility of basic management choices:
 - A.

Awake Intubation	vs.	Intubation Attempts After Induction of General Anesthesia
------------------	-----	---
 - B.

Non-Invasive Technique for Initial Approach to Intubation	vs.	Invasive Technique for Initial Approach to Intubation
---	-----	---
 - C.

Preservation of Spontaneous Ventilation	vs.	Ablation of Spontaneous Ventilation
---	-----	-------------------------------------

What about
muscle relaxants?



Spontaneous Ventilation

vs. Muscle Relaxants

PROS:

- Pharyngeal muscle tone preserved and upper airway patency maintained
- Maintain oxygenation
- Safety

CONS:

- Coughing
- Laryngospasm
- Moving target
- ETT passage

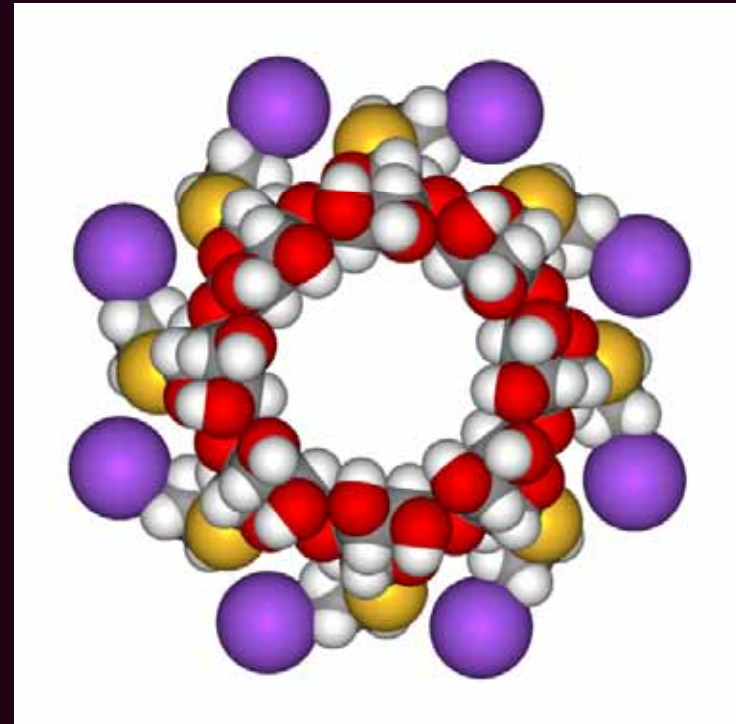
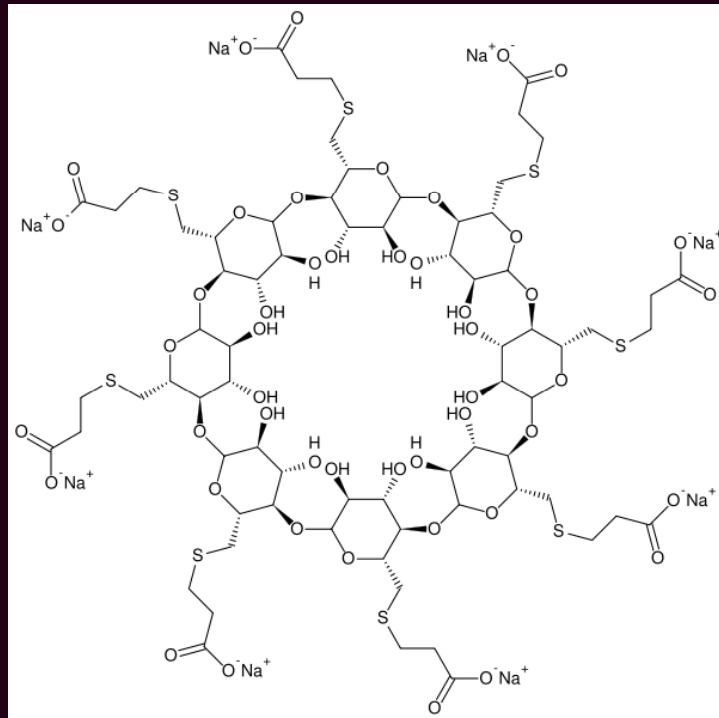
PROS:

- No coughing
- Motionless target
- “Optimal intubating conditions”

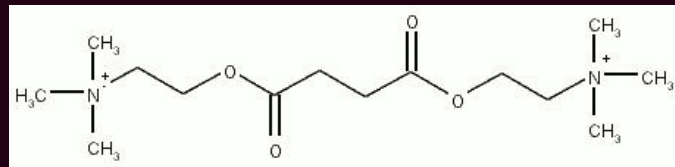
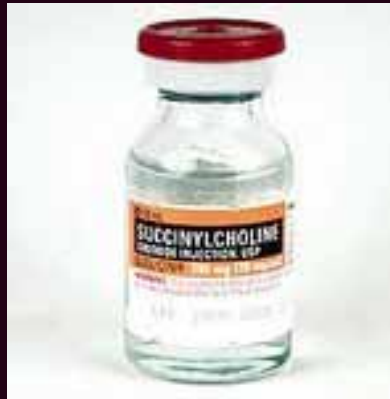CONS:

- Upper airway soft tissue collapse
- Rapid desaturation w/ apnea
- May lose ability to ventilate
- Gastric insufflation

Sugammadex Sodium

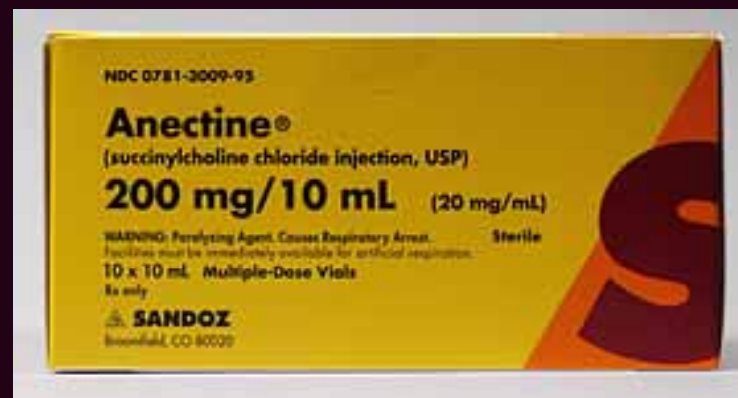

Succinylcholine



Cardiac Arrest Risk (Peds)

rare acute rhabdomyolysis w/ hyperkalemia followed by ventricular dysrhythmias, cardiac arrest, and death after admin. to apparently healthy children subsequently found to have undiagnosed skeletal muscle myopathy, most frequently Duchenne's muscular dystrophy; peaked T-waves, sudden cardiac arrest w/in minutes after admin.; usually males <8 yo but also reported in adolescents; treat for hyperkalemia if cardiac arrest w/ no other cause develops soon after admin.; reserve use in children for emergency intubation or need for immediate secure airway



When do we consider giving a muscle relaxant?

- When we've already given it
- When you are confident that it will not impair your ability to ventilate
- When using a laryngeal mask as an intubation conduit
- When using a lighted stylet
- Think about it for every patient!

Tracheal Intubation Tools: 2010



Flexible Bronchoscope

- The “Gold Standard” tool for difficult airway management
- The most versatile instrument
- Mandatory tool and skill for every practitioner
- Improved image quality with new scopes

Flexible Bronchoscope

Limitations:

- Optical problems with fogging, blood, or secretions
- Not intuitive
- Significant learning curve
- Requires practice to acquire and maintain skills
- Expensive
- Fragile

Video/Optical Laryngoscopy

- Skill set overlaps with direct laryngoscopy
- Intuitive use
- Does not require neck extension
- Portable
- Neonates – Adults

Video/Optical Laryngoscopy

- Fogging, blood, secretions
- Mouth opening required
- Best for oral intubation

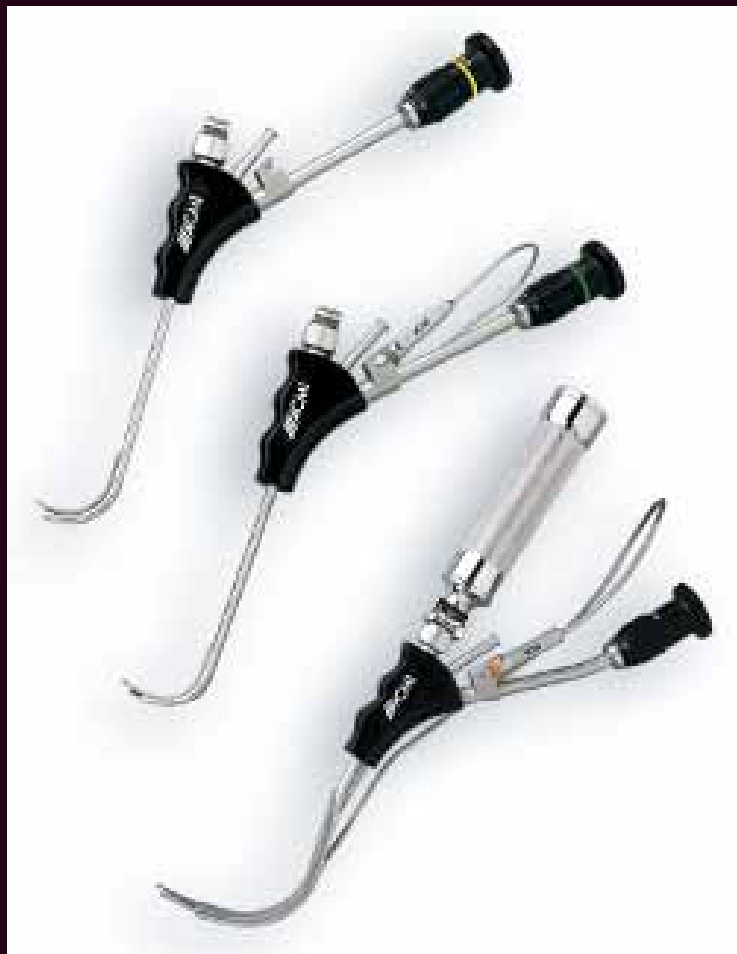Video/Optical Laryngoscopy

- Looking at the monitor or through the eyepiece can distract you from what you are doing with your hands
- While similar to direct laryngoscopy, it is a different skill set
- More than what meets the eye: common problem is having an excellent view of the glottis and having trouble advancing tube into trachea

The Bullard Laryngoscope

A New Indirect Oral Laryngoscope (Pediatric Version)

Lawrence M. Borland, MD and Margaretha Casselbrant, MD



- Invented by Dr. Roger Bullard, the father of modern indirect laryngoscopy
- First indirect laryngoscope designed for difficult airways
- Current indirect laryngoscopes incorporate variations of this design

Airtraq Optical Laryngoscope



- Lens warmer prevents fogging
- Only completely disposable single-use optical laryngoscope
- Inexpensive
- Portable
- Easy to setup
- Well suited for non-operating room settings

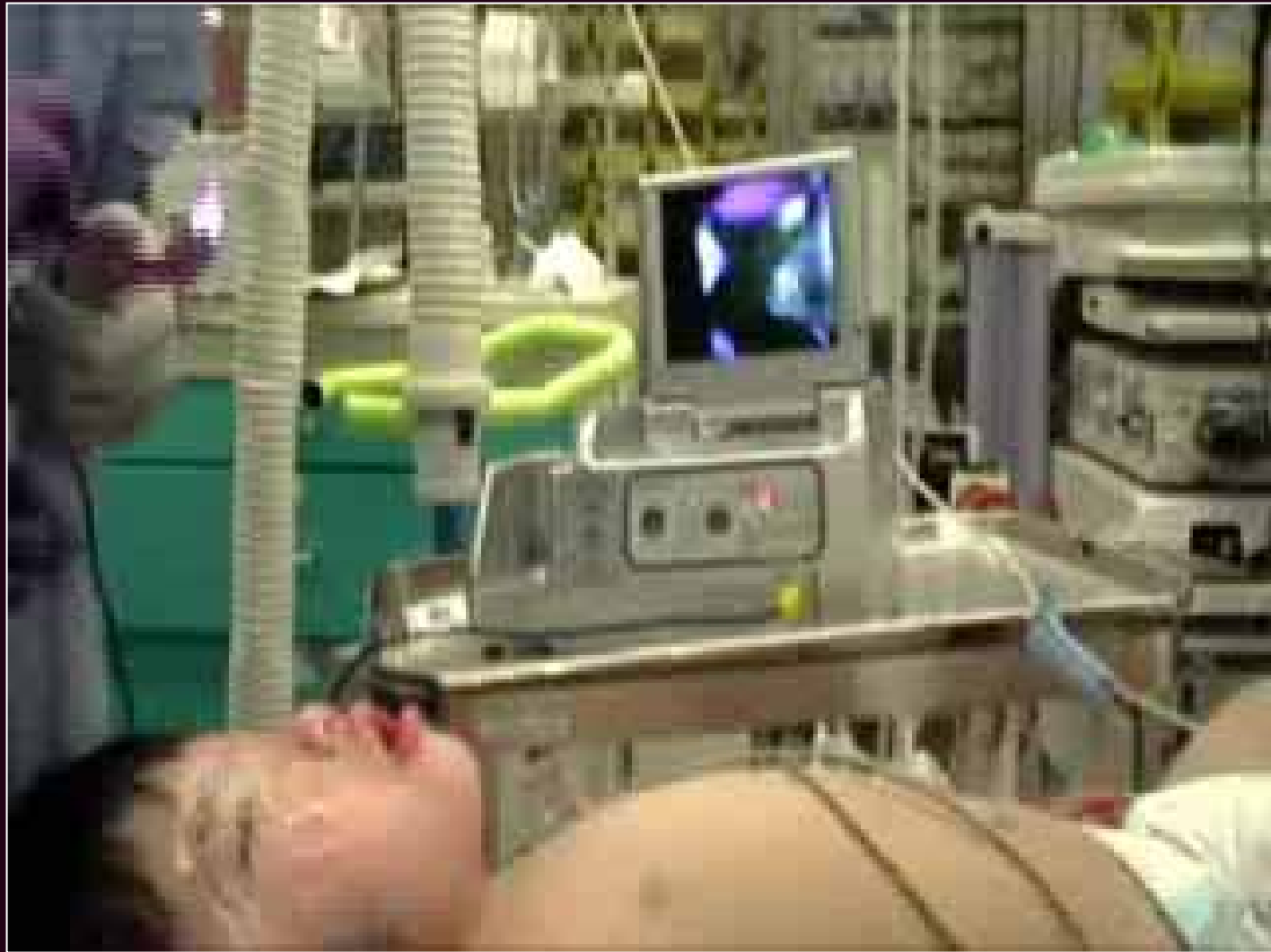Airtraq Optical Laryngoscope



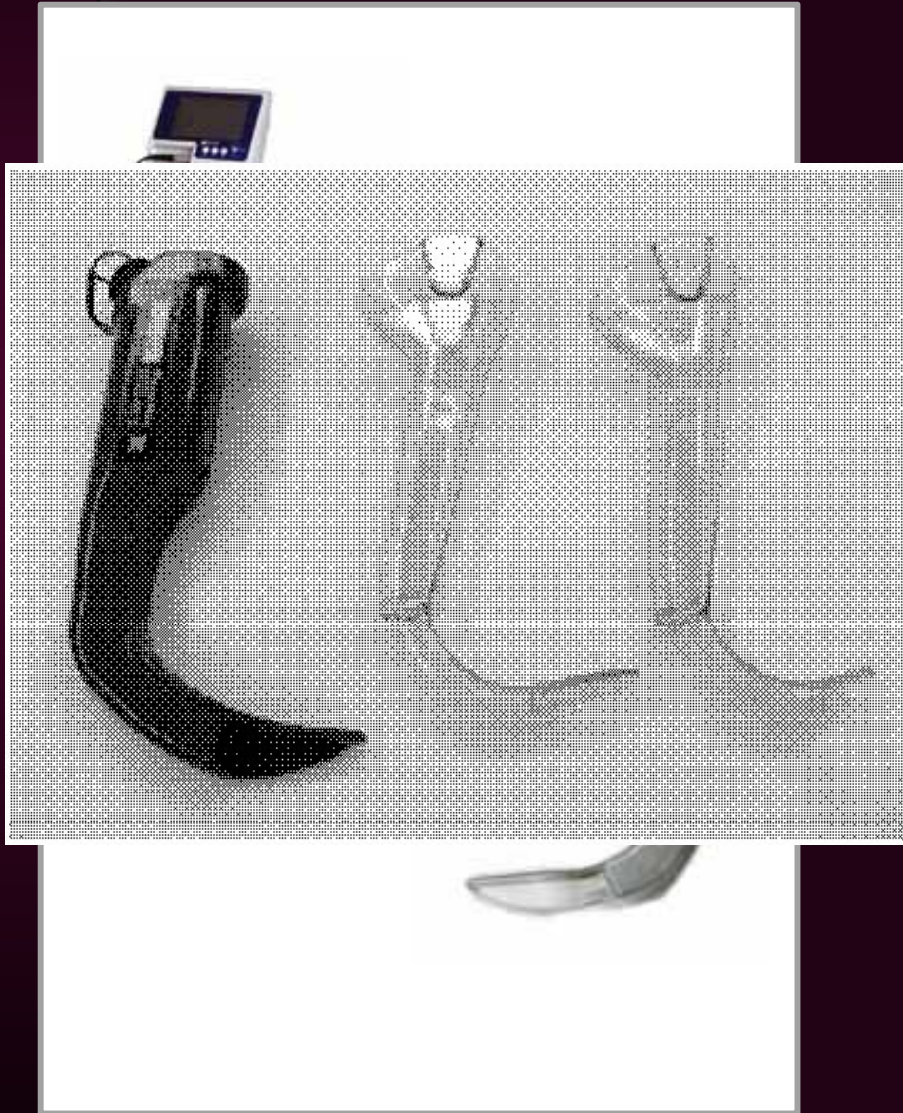Limitations:

- Best for oral intubations
- Some mouth opening is required
- Learning curve
- Can get lost when attention is through eyepiece
- Caution with insertion

Airtraq optical laryngoscope in a child with hemifacial microsomia and limited mouth opening



Glidescope Cobalt



- Reusable video baton that slides into disposable plastic blades/handles
- Similar to Macintosh blade design
- Warming at lens limits fogging
- Relatively portable
- Simple to setup
- Intuitive use

*Comparison of the Cobalt Glidescope® video laryngoscope with conventional laryngoscopy in simulated normal and difficult infant airways**

MICHELLE WHITE MB ChB DCH FRCA, NICOLA WEALE
BM BS FRCA, JUDITH NOLAN MB BS MRCP FRCA, STEVEN
SALE MB ChB FRCA AND GUY BAYLEY MB BS MRCP FRCA
Department of Paediatric Anaesthesia, Bristol Royal Hospital for Children, Bristol, UK

British Journal of Anaesthesia 101 (4): 531–4 (2008)
doi:10.1093/bja/aen234 Advance Access publication August 8, 2008

BJA

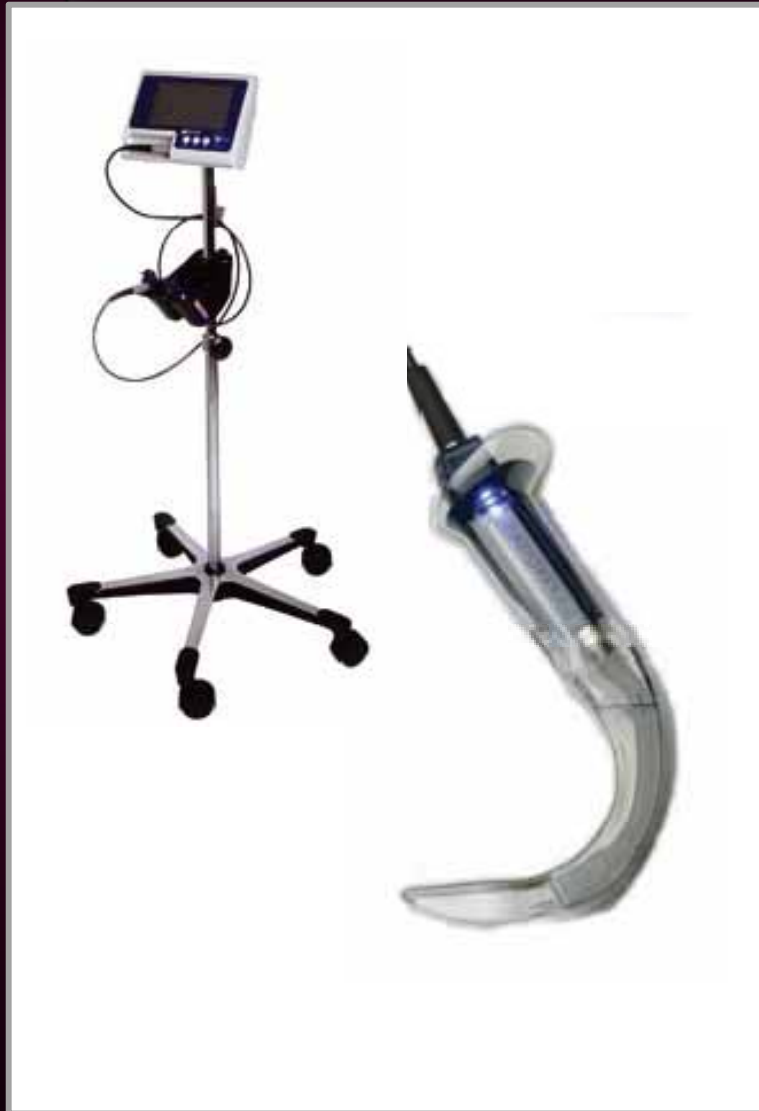GlideScope® video laryngoscope: a randomized clinical trial in 203 paediatric patients†

J.-T. Kim, H.-S. Na, J.-Y. Bae, D.-W. Kim, H.-S. Kim*, C. S. Kim and S. D. Kim

Validation of the glidescope video laryngoscope in pediatric patients

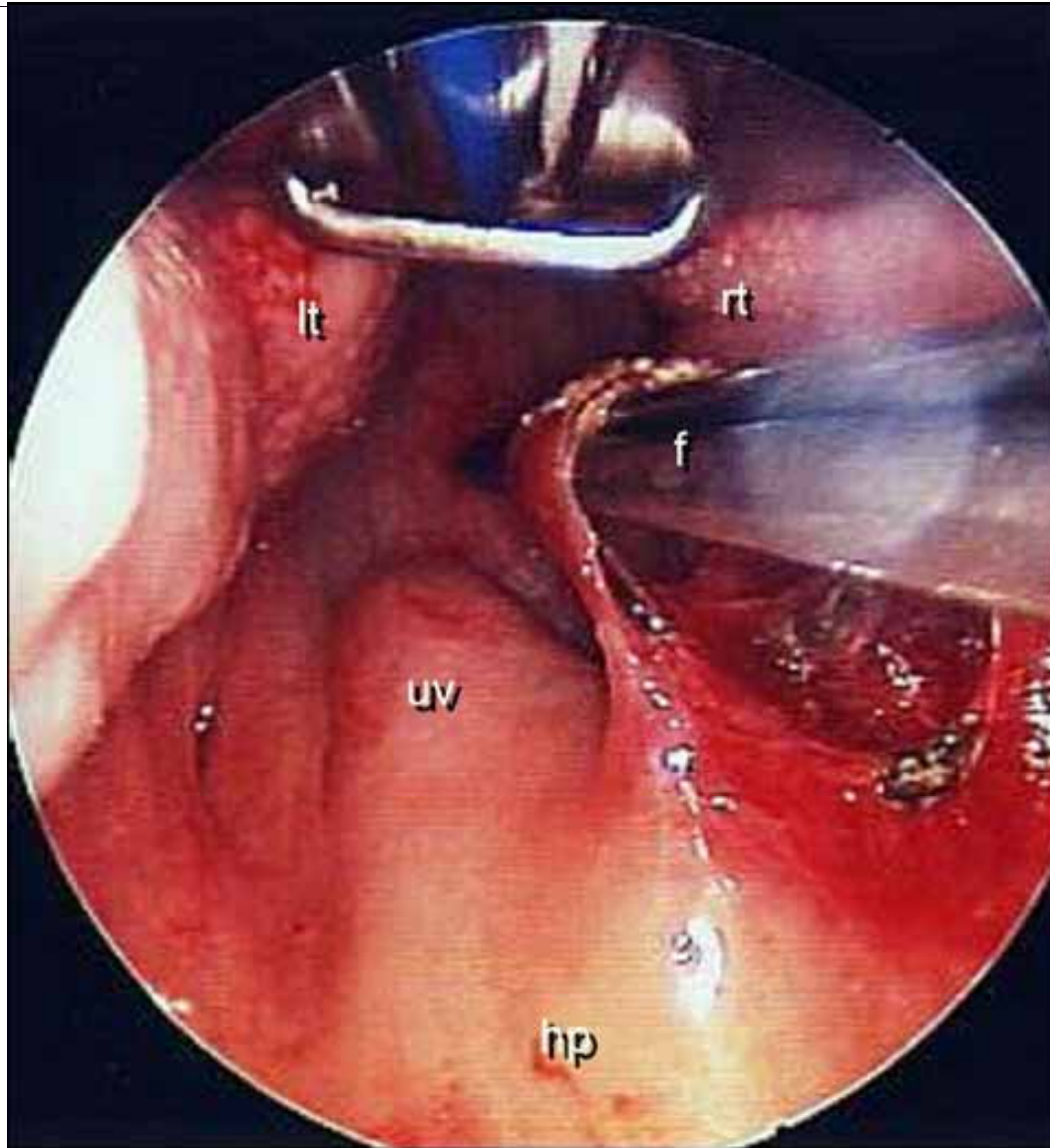
ANDREAS REDEL MD*, FUNDA KARADEMIR MSc†,
ANETT SCHLITTERLAU MD*, MATTHIAS FROMMER MD‡,
LARS-UWE SCHOLTZ MD§, PETER KRANKE MD‡,
FRANZ KEHL MD PhD DEAA¶, NORBERT ROEWER MD PhD**
AND MARKUS LANGE MD‡

Glidescope Cobalt



Limitations:

- Some mouth opening is required
- Learning curve
- Difficulty passing tube despite excellent view
- Caution with insertion of scope and styletted tube



From: Choo M *et al.* Another complication associated with videolaryngoscopy. *Can J Anaesth* 2007; 54: 322-4

Storz Video Laryngoscope



- Available blade designs mimic Miller 1, Miller 3, and Macintosh 3
- Can be used for direct laryngoscopy
- Teaching tool for laryngoscopy

A comparison of the STORZ video laryngoscope and standard direct laryngoscopy for intubation in the Pediatric airway – a randomized clinical trial

ARNIM VLATTEN MD*†, SYLVIE AUCOIN MD†, SHARON LITZ MD*†,
BRIAN MACMANUS MD*† AND CHRIS SODER MD*†

Management of the Difficult Infant Airway with the Storz Video Laryngoscope: A Case Series

Rebecca S. Hackell, AB Paul A. Stricker, MD

Lisa D. Held, DO John E. Fiadjoe, MD

Pediatric airway management: comparing the Berci–Kaplan Video Laryngoscope with direct laryngoscopy

DAVID MACNAIR MB CHB FRCA, DAN BARACLOUGH MBCHB, FRCA, GRAHAM WILSON MB CHB FRCA, MARK BLOCH MB CHB FRCA AND THOMAS ENGELHARDT MD PHD FRCA

Department of Paediatric Anaesthesia, Royal Aberdeen Children's Hospital, Aberdeen, UK

The Efficacy of the Storz Miller 1 Video Laryngoscope in a Simulated Infant Difficult Intubation

John E. Fiadjoe, MD* Rebecca S. Hackell, AB* Harshad Gurnaney, MD* Ronald S. Litman, DO*

Paul A. Stricker, MD* Abdul Salam, MS† Mohamed A. Rehman, MD*

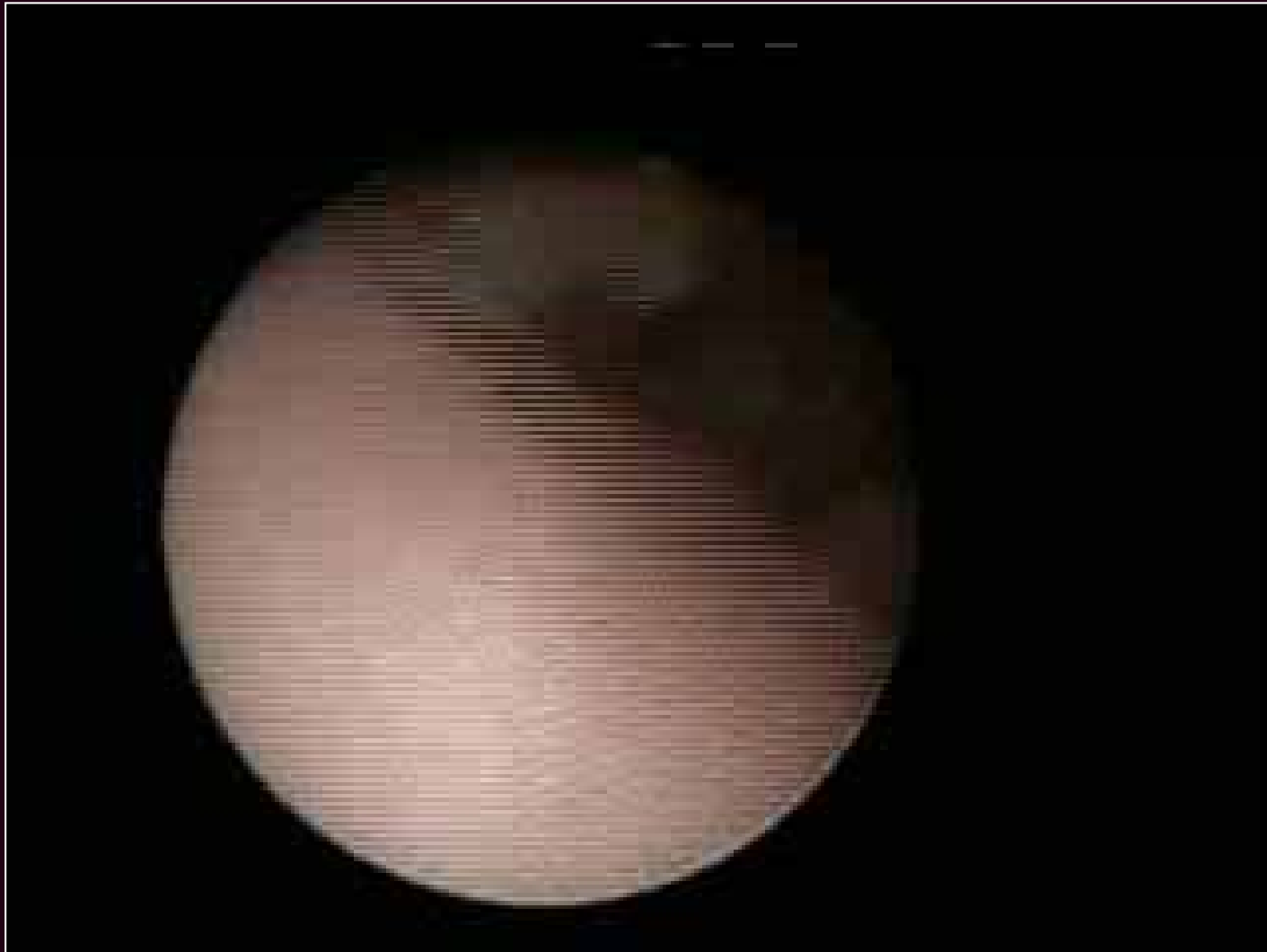Storz Video Laryngoscope



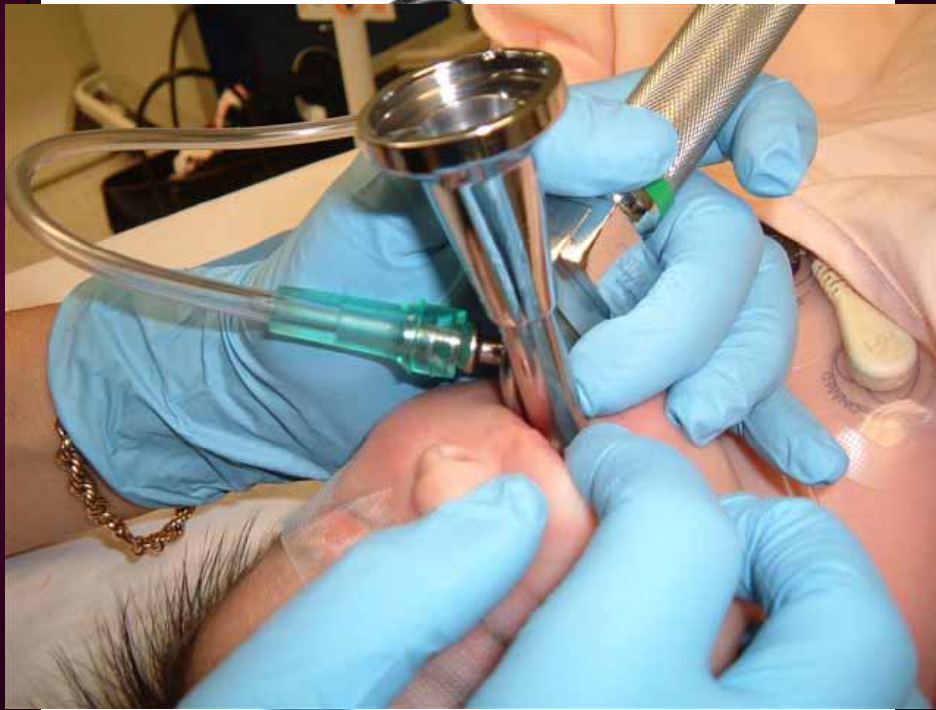Limitations:

- Some mouth opening is required
- Learning curve
- No Macintosh/Miller 2 blade
- Difficulty passing tube despite excellent view
- Caution with insertion of scope and stylet tube
- Pediatric sizes not as portable
- Magnified, close-up image

Magnified Grade 1 view
with Storz Video Laryngoscope in a 15mo
with the Pierre Robin Sequence



Truphatek EVO2



- Laryngoscope blade with angulated tip and incorporated optics and view port
- Portable
- Infant blade with port for O₂ insufflation

A comparison of Truview infant EVO2 laryngoscope with the Miller blade in neonates and infants

RANJU SINGH MD, PUSHPINDER SINGH DA DNB AND
HOMAY VAJIFDAR MD

- Study in subjects with normal airway anatomy
- Clinically insignificant differences in intubation times (16 vs. 18 sec)
- Improved laryngoscopic view with Truview EVO2

Optical Stylets

- Rigid stylet with a light source and optical fibers that deliver an image from the tip to an eyepiece or a camera.
- Loaded with a tracheal tube in the same fashion as with a lighted stylet
- The Shikani Optical Stylet and the Storz Bonfils are examples available in pediatric sizes

The Optical Stylet—A New Intubation Technique for Adults and Children with Specific Reference to Teaching

RONALD L. KATZ, M.D.,* AND GEORGE BERCI, M.D.†

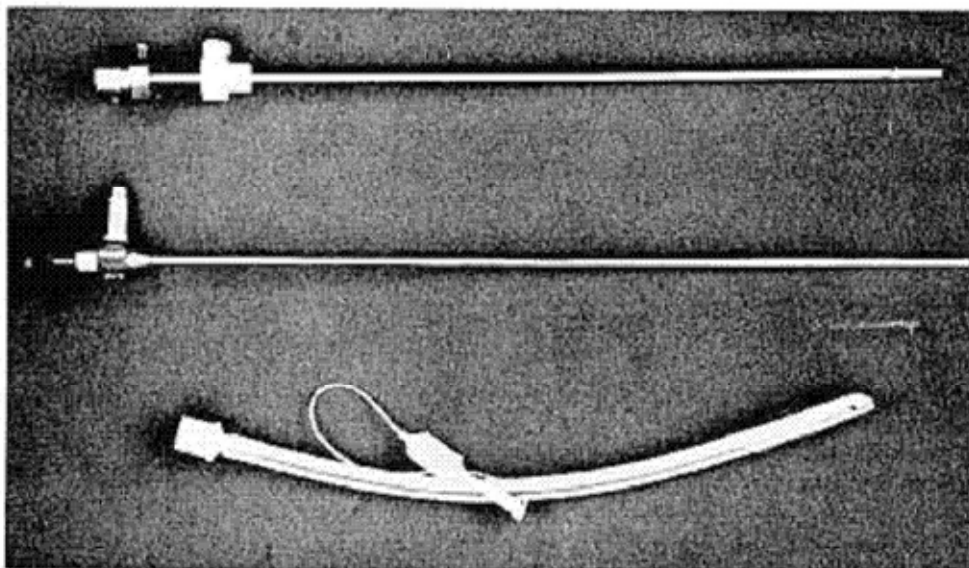


FIG. 1 (*above*). Intubating (optical stylet) set up. *Bottom*, standard endotracheal tube. *Middle*, telescope with 0-degree straight wide-angled view with built-in fiberoptic illumination. *Top*, Anti-fog sheath with cone-shaped adjustable adaptor.

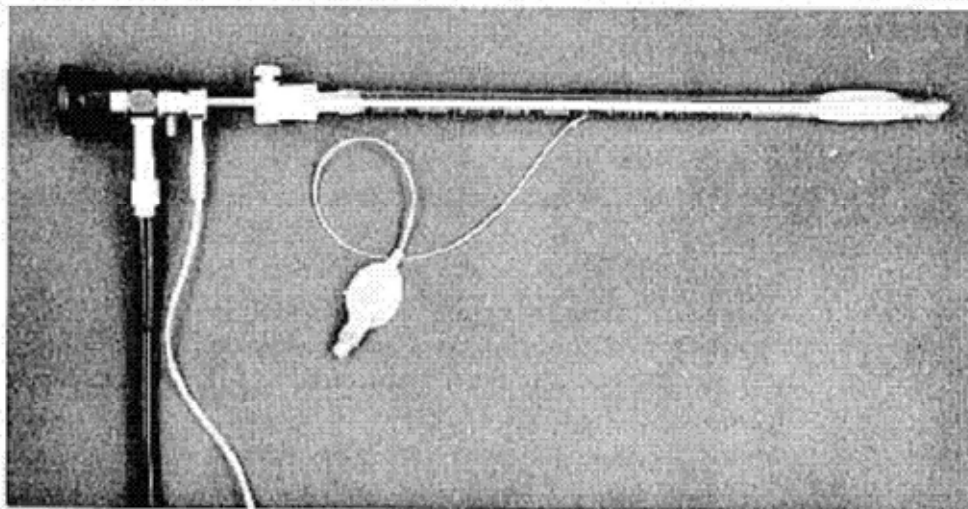


FIG. 2 (*below*). Assembled optical stylet introduced into the endotracheal tube. The optic is slightly recessed. The beveled tip of the endotracheal tube can be seen at one corner of the viewing field and can be used to lift up the overhanging epiglottis under visual control.

Optical Stylets

- Rigid scope can displace soft tissue
- More intuitive than flexible bronchoscope
- Does not require neck extension
- Stylet is malleable
- Can deliver oxygen
- Portable
- Compatible with video camera head
- Relatively inexpensive
- Neonates – Adults

Optical Stylets

Limitations:

- Optical problems: fogging, blood, and secretions
- Learning curve
- Optical fibers break over time
- Poorly suited for nasal intubations
- Getting lost when attention is through the eyepiece

Shikani Optical Stylet (SOS)



- Rigid fiberoptic optical stylet
- Malleable
- O2 insufflation port
- Portable

Storz Bonfils



- Rigid fiberoptic optical stylet
- Non-malleable
- Excellent optics
- Portable
- Retromolar technique

Storz Bonfils

Pediatric Anesthesia 2008 18: 1040–1044

Evaluation of the pediatric bonfils fiberscope for elective endotracheal intubation

BERTHOLD BEIN MD DEAA, FRANK WORTMANN MD,
PATRICK MEYBOHM MD, MARKUS STEINFATH MD,
JENS SCHOLZ MD AND VOLKER DÖRGES MD

- 55 children, normal airway exam, ages 6±4yrs
- High failure rate (>5%) after 3 attempts
- Secretions obscuring optics responsible for failures

Storz Bonfils

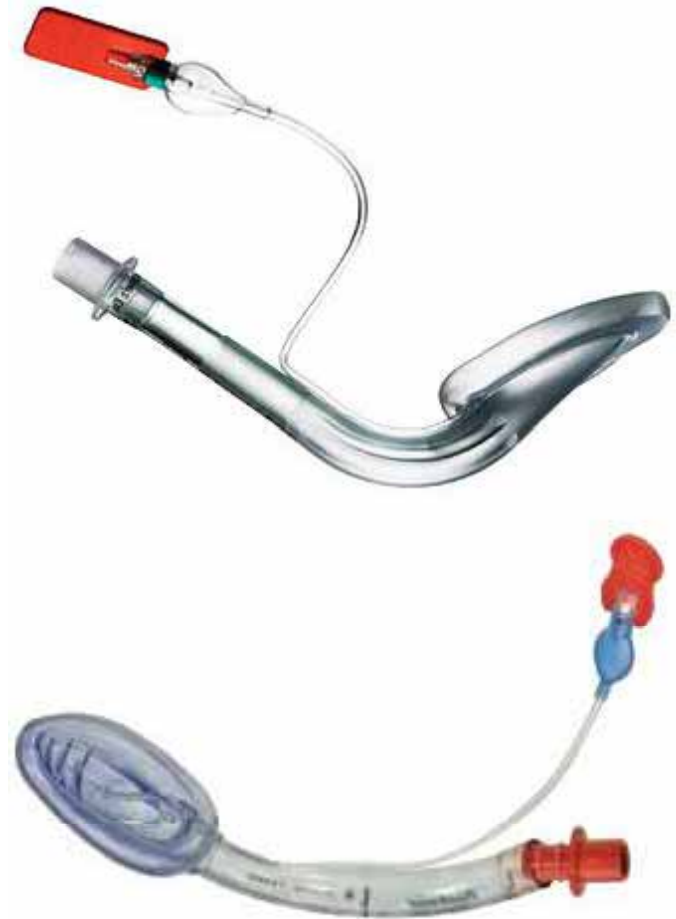
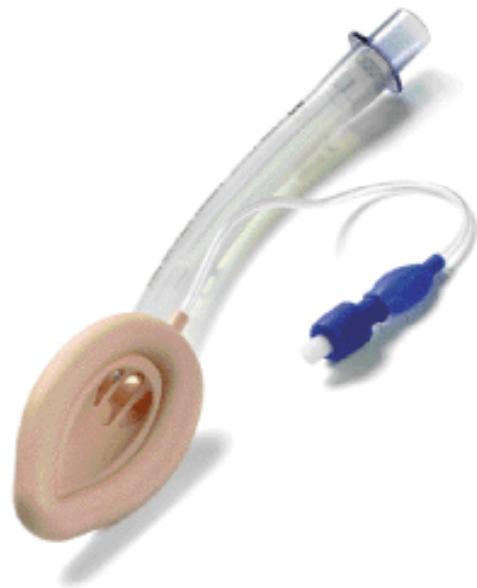Limitations



- Not malleable
- Users report more difficult to use^{*}
- Significant learning curve

^{*}Powell *et al.* Comparison of the performance of four laryngoscopes in a high-fidelity simulator using normal and difficult airway. *Br J Anaesth* 2009; 103(5): 755-760.

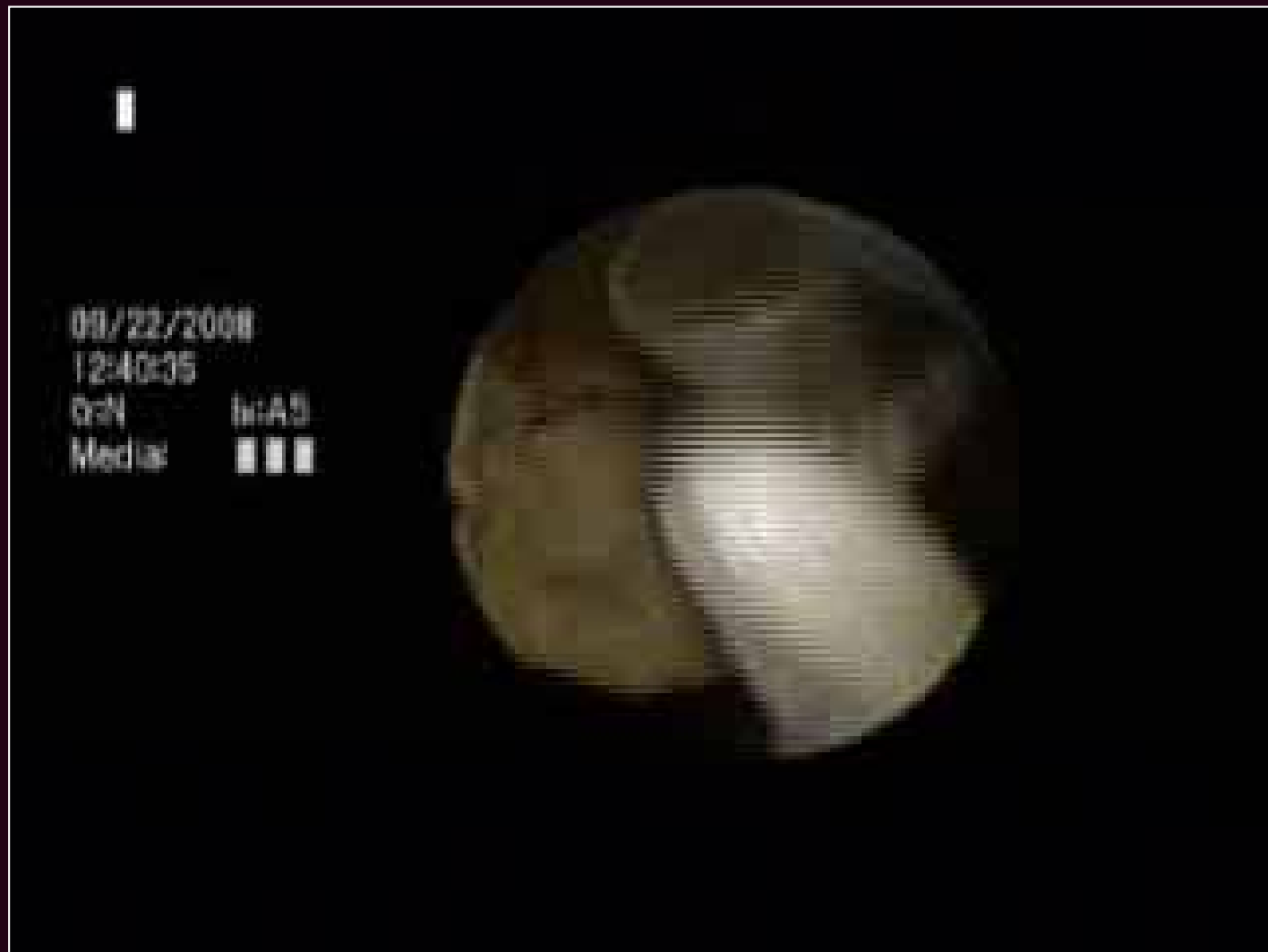Laryngeal Masks as Intubation Conduits



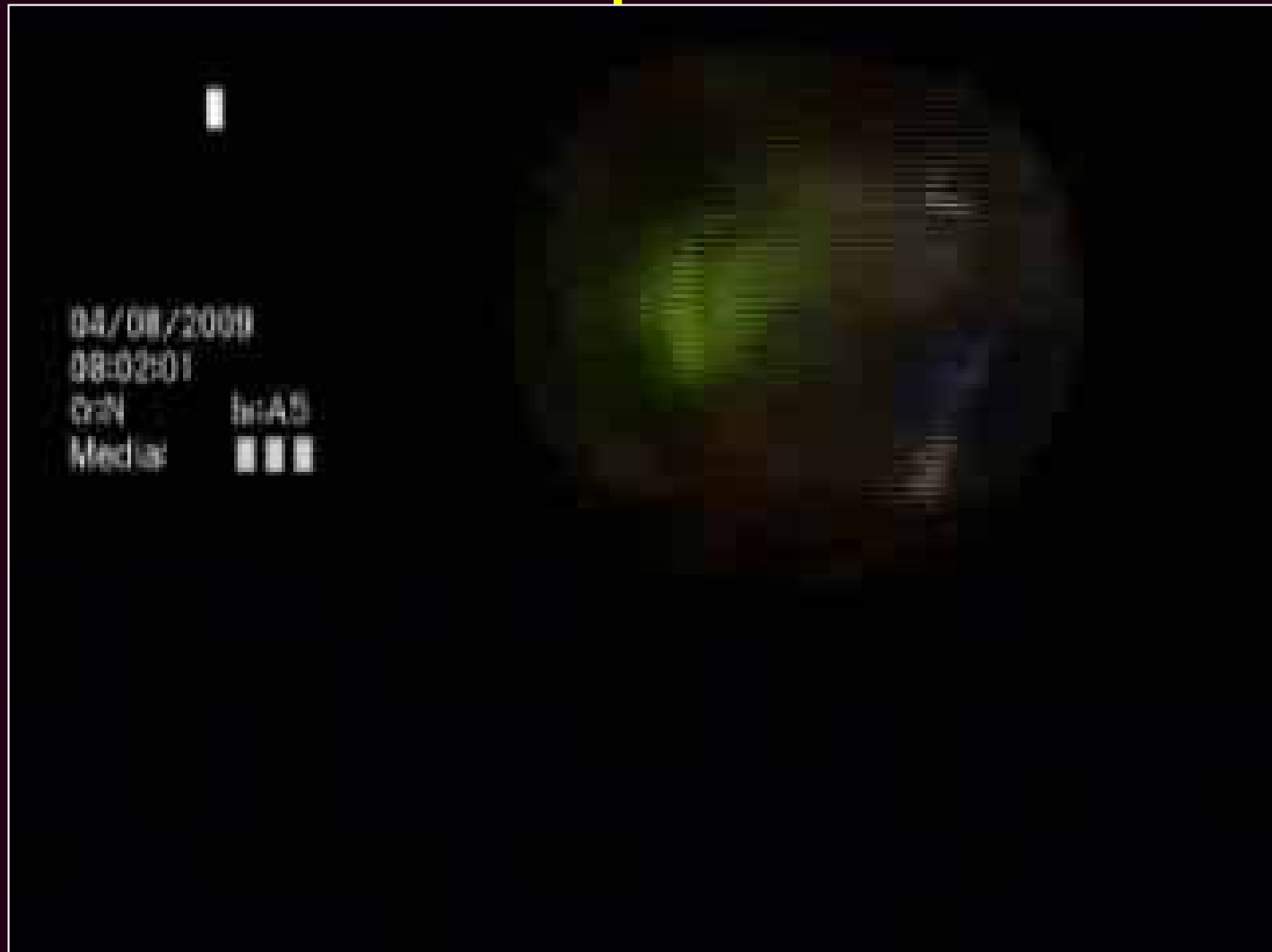Fiberoptic Intubation Through a Laryngeal Mask

- Blind intubation not recommended
- Ventilation can be provided during intubation attempts
- Barrel of LM eliminates difficulties of navigating an endoscope through the upper airway
- Distal opening of LM is often at the glottis

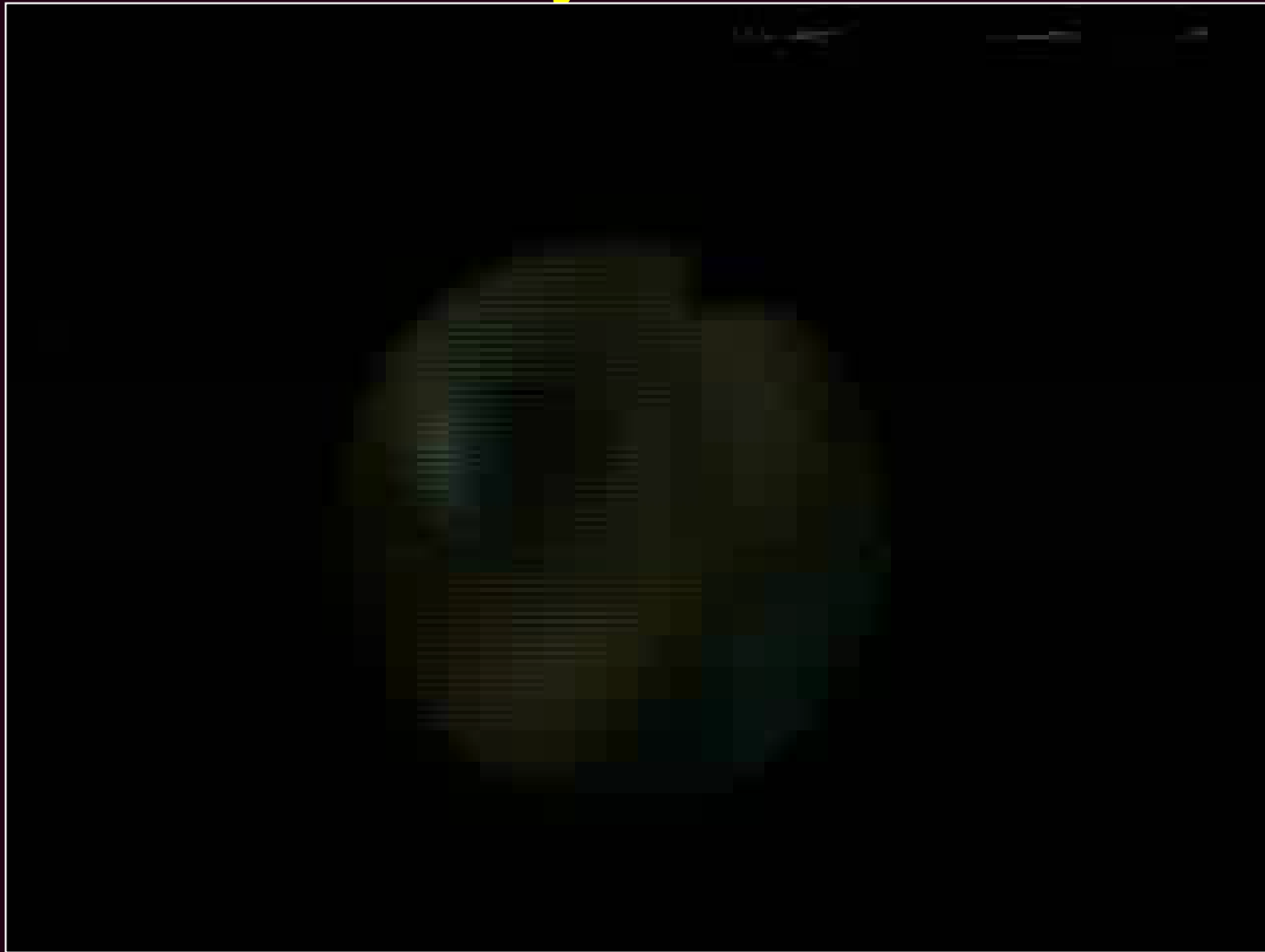
FOI Through a Laryngeal Mask in an 11mo with Goldenhar Syndrome



FOI Through an air-Q Laryngeal Mask in a 7mo with Pierre Robin Sequence



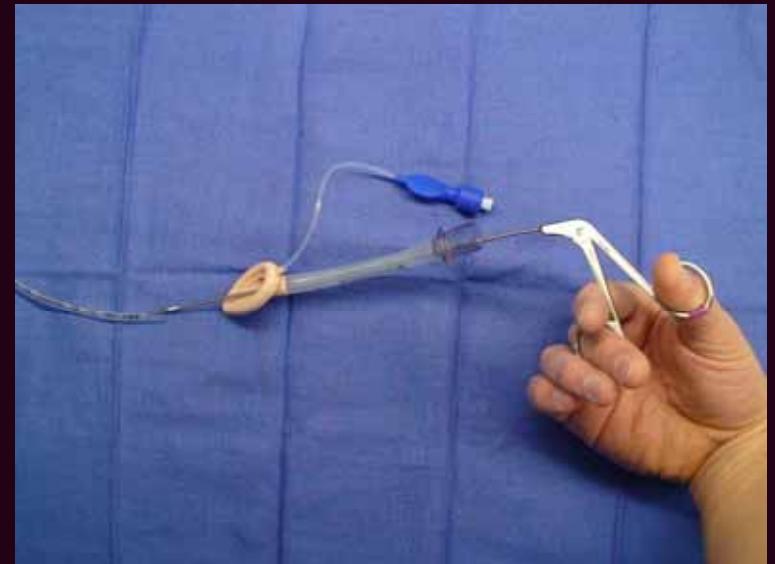
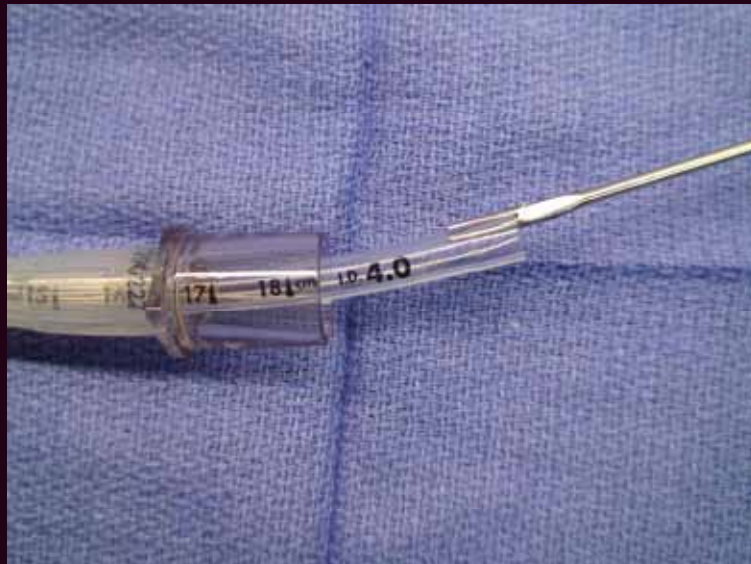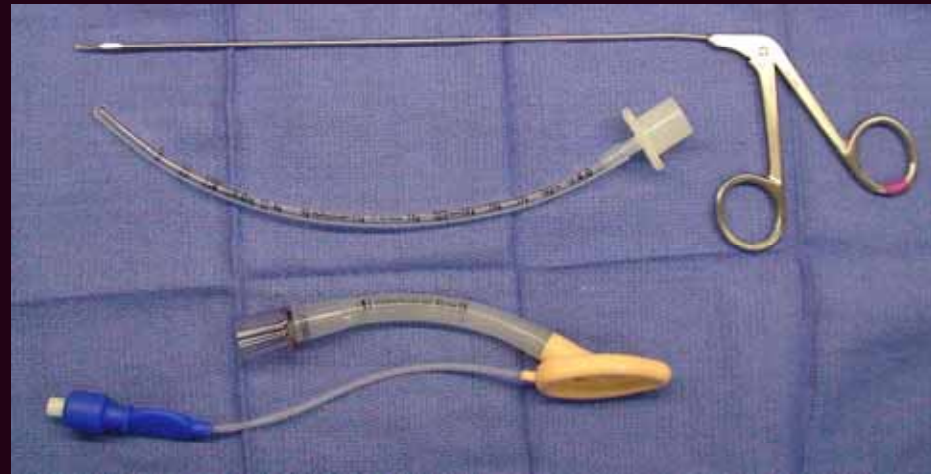
FOI Through an air-Q Laryngeal Mask in an 8mo with Edwards Syndrome



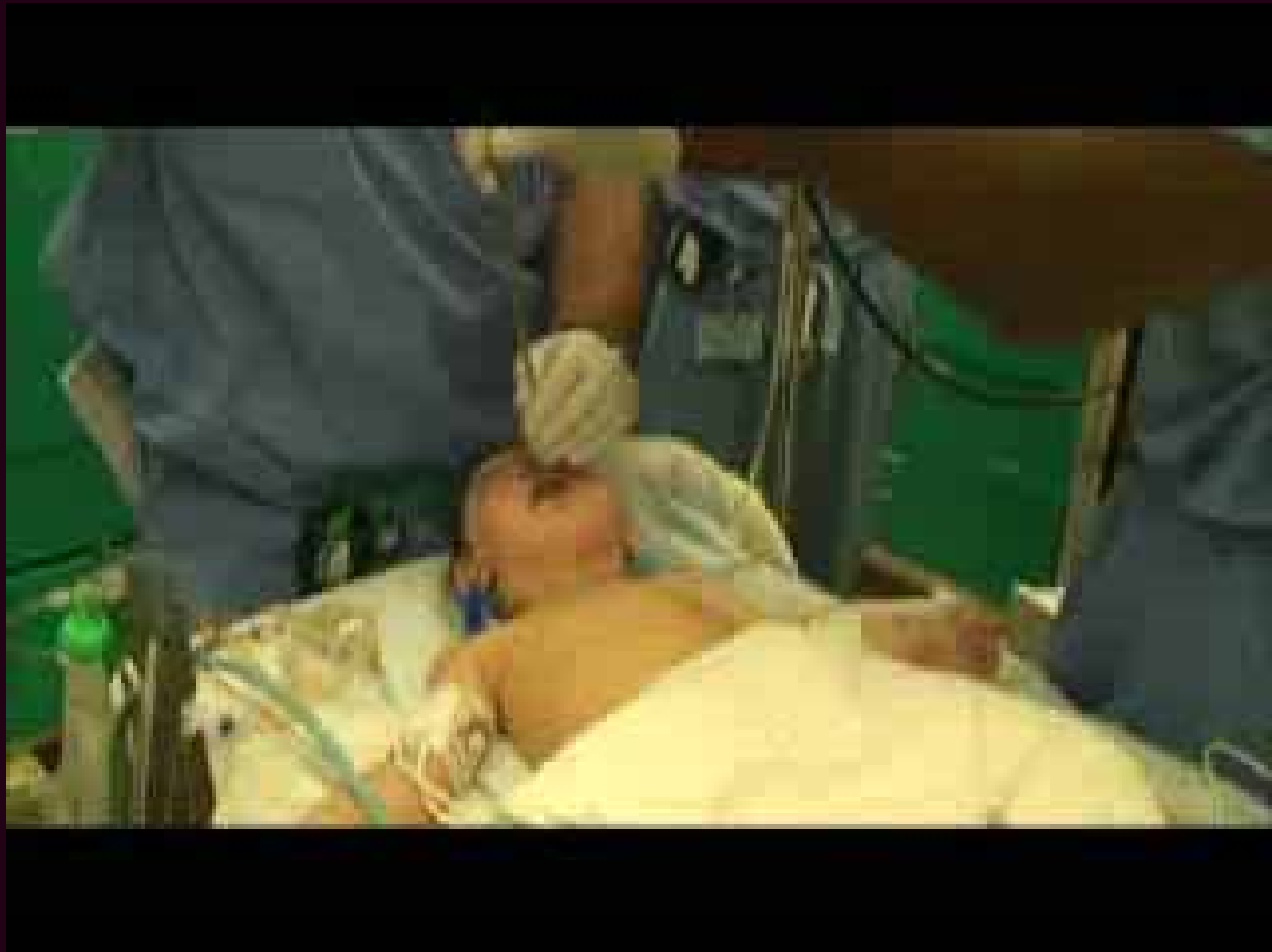Fiberoptic Intubation Through a Laryngeal Mask

- More complicated technique, particularly in children
- Smaller LMs may not allow passage of pilot balloon of cuffed tubes
- Uncuffed tubes may prove too small, requiring tube exchange
- LM must be removed to secure tube, risk of dislodgement in process

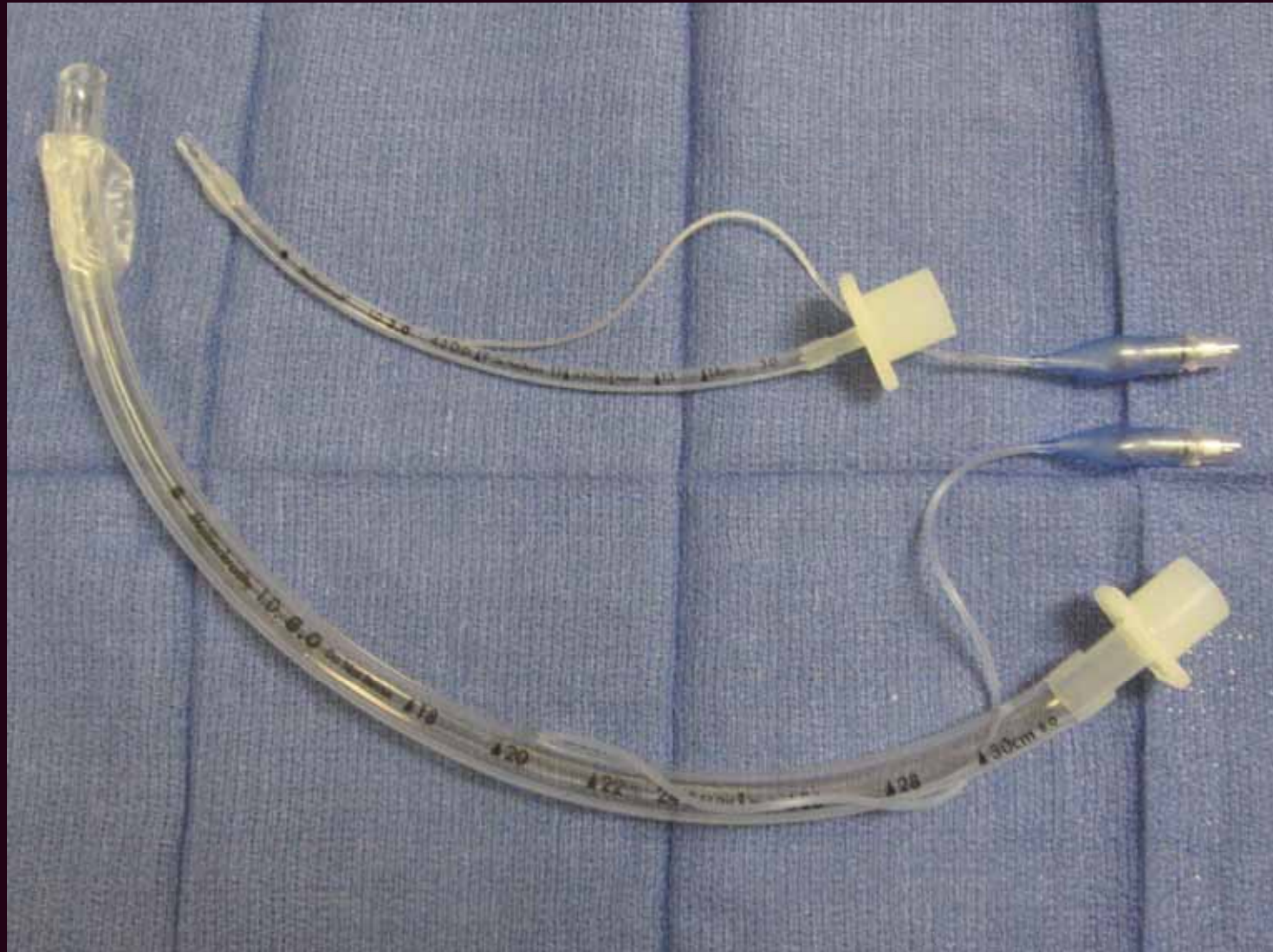
Removing the LMA following Intubation: Laryngeal Forceps



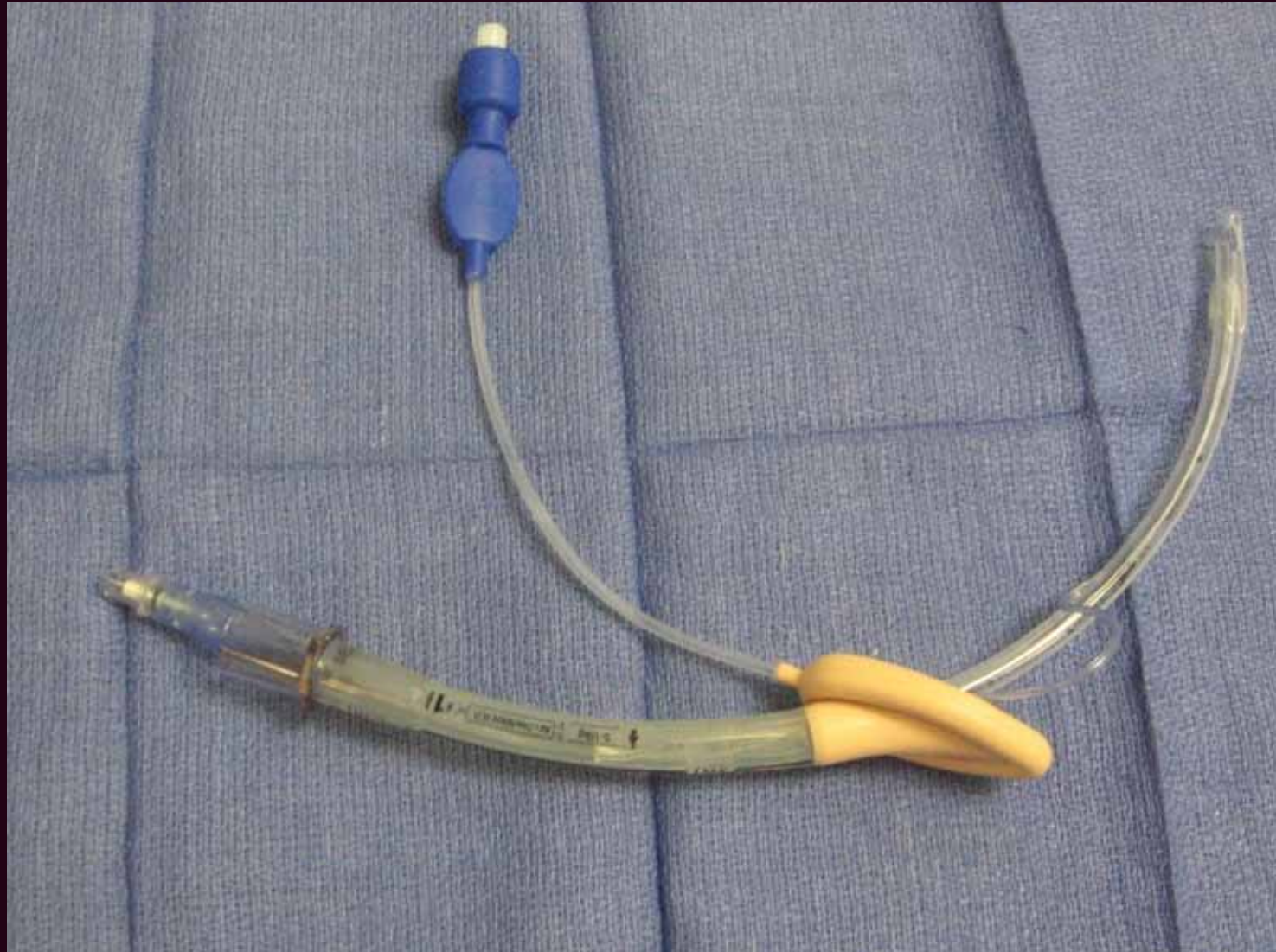
Removing the LMA following Intubation: Laryngeal Forceps



Special Consideration: The Pilot Balloon



Special Consideration: The Pilot Balloon

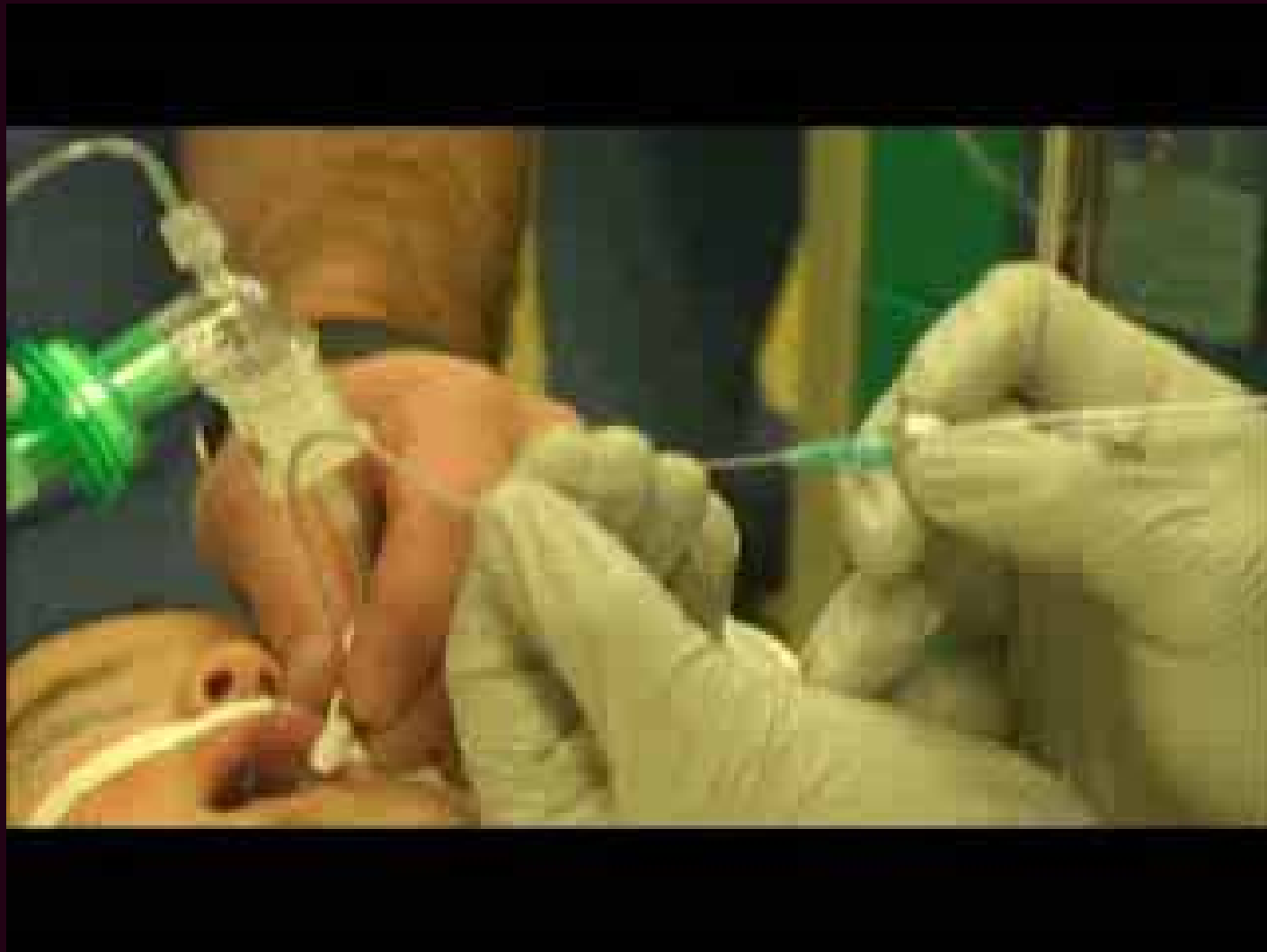

Dealing with the Pilot Balloon

Possible solutions:

- Use an uncuffed tube; perform tube exchange if undersized
- Cut the pilot balloon off and reconstruct one after intubation
- Use a laryngeal mask which is designed for use as an intubation conduit and allows passage of the pilot balloon (air-Q)

Solution: Remove the Pilot Balloon and Replace It after Intubation



Lighted Stylet Intubation in Pediatrics

- Easily learned and high success rate
- Inexpensive, compact, and easily cleaned
- Need not visualize the larynx: simple and rapid
- Not hindered by blood and secretions
- Effective in cases of micrognathia and TMJ disease
- Useful in pediatric cervical spine instability

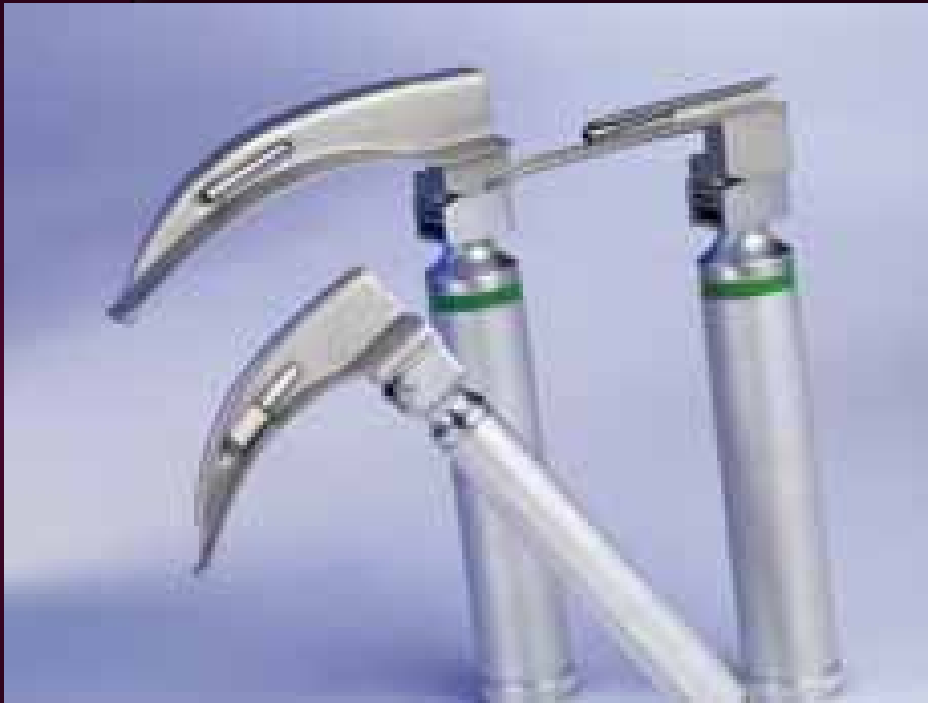Fisher QA. J Clin Anesth 1997;9:275

Berns SD. Acad Em Med 1996;3:34

Lighted Stylets

- **Contraindications**
 - Airway tumor
 - Retropharyngeal abscess
 - Laryngeal fracture
 - Tracheal disruption
- **Relative Disadvantages**
 - Requires practice
 - May cause bleeding
 - Room lights must be dimmed
 - Problematic in obese patients

What about Direct Laryngoscopy?



“He that is good with a hammer tends to think everything is a nail.”
-Abraham Maslow

What about Direct Laryngoscopy?

When To:

- Suspected but not confirmed difficult DL
- Previously difficult but interval H&P suggest DL feasible
- Consider using VL
- Do not perseverate

When Not To:

- Recent DL confirmed
- History/exam highly predictive
- When DL may confound subsequent attempts
- When surgery will alter airway

Airway Management Techniques

- Flexible fiberoptic intubation while maintaining spontaneous ventilation with a modified nasal trumpet
- Flexible fiberoptic intubation through a laryngeal mask with continuous ventilation throughout using a bronchoscope adaptor

The Modified Nasal Trumpet Maneuver

Charles Beattie, PhD, MD

Department of Anesthesiology, Vanderbilt University, Nashville, Tennessee

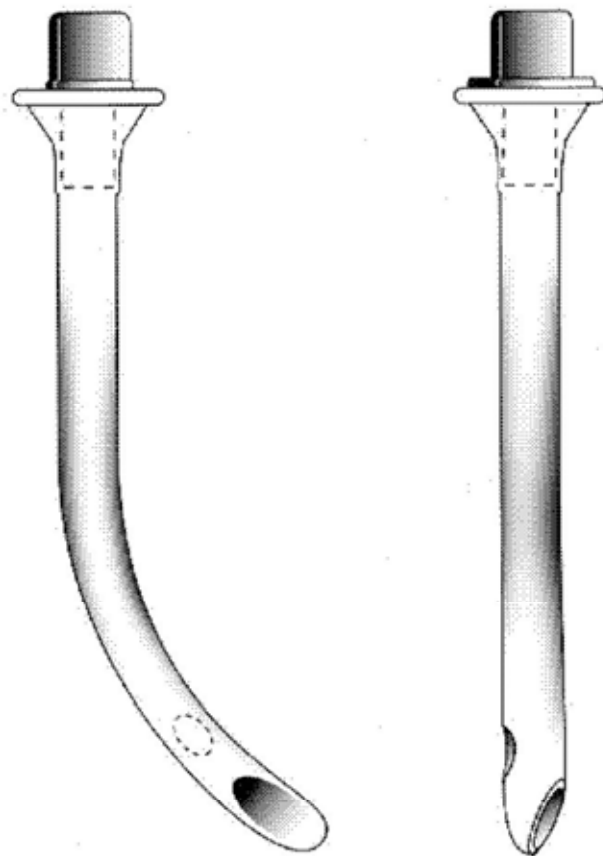
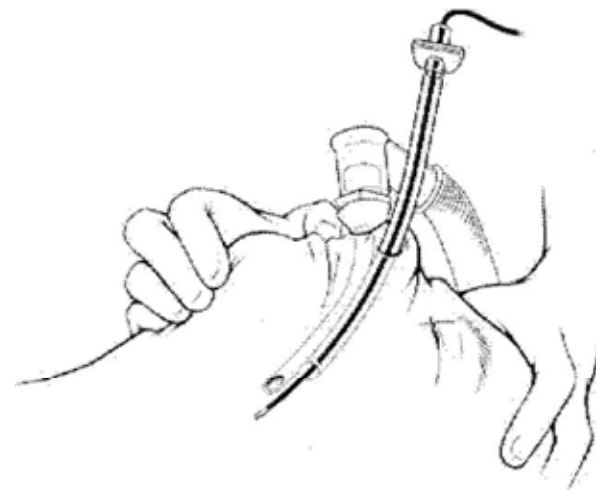


Figure 1. The Modified Nasal Trumpet (MNT). Ordinary nasal airway with an endotracheal tube (ETT) connector wedged into the flared end. Also shown is an optional "Murphy eye," a fenestration cut (with scissors) into the distal end opposite and slightly proximal to the bevel.

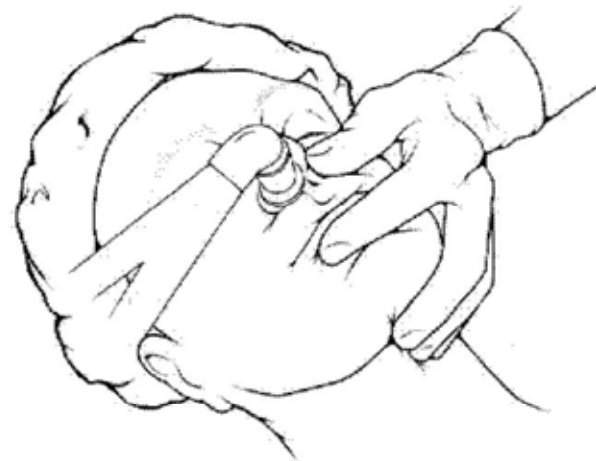

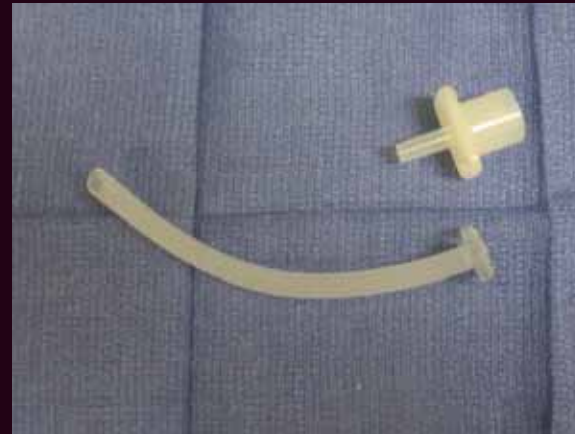Figure 2. Patient being ventilated (control or assist) through the modified nasal trumpet (MNT), which has been placed in the right nostril. Note mouth and lips held firmly shut and other naris occluded with thumb.

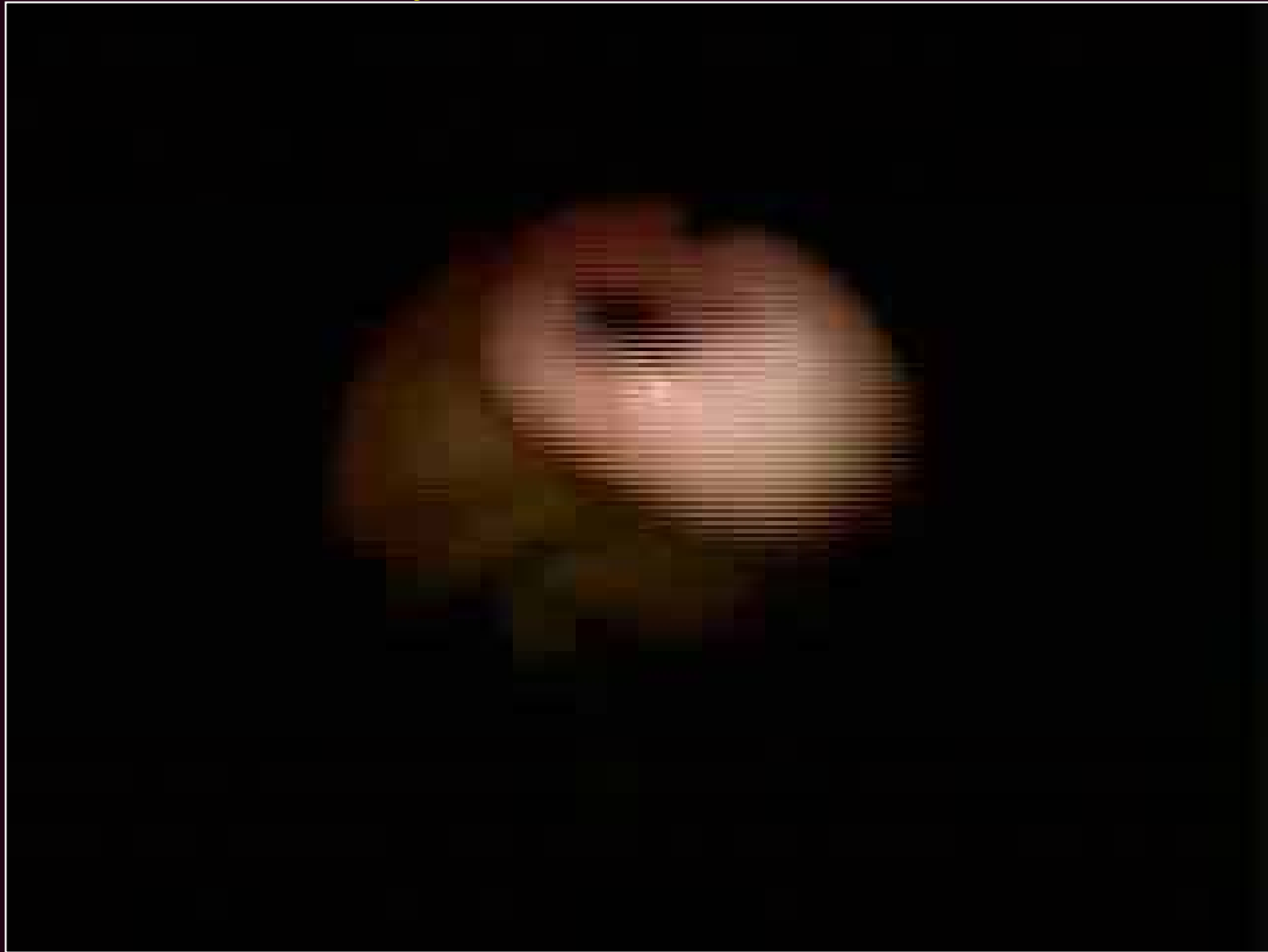

The Modified Nasal Trumpet

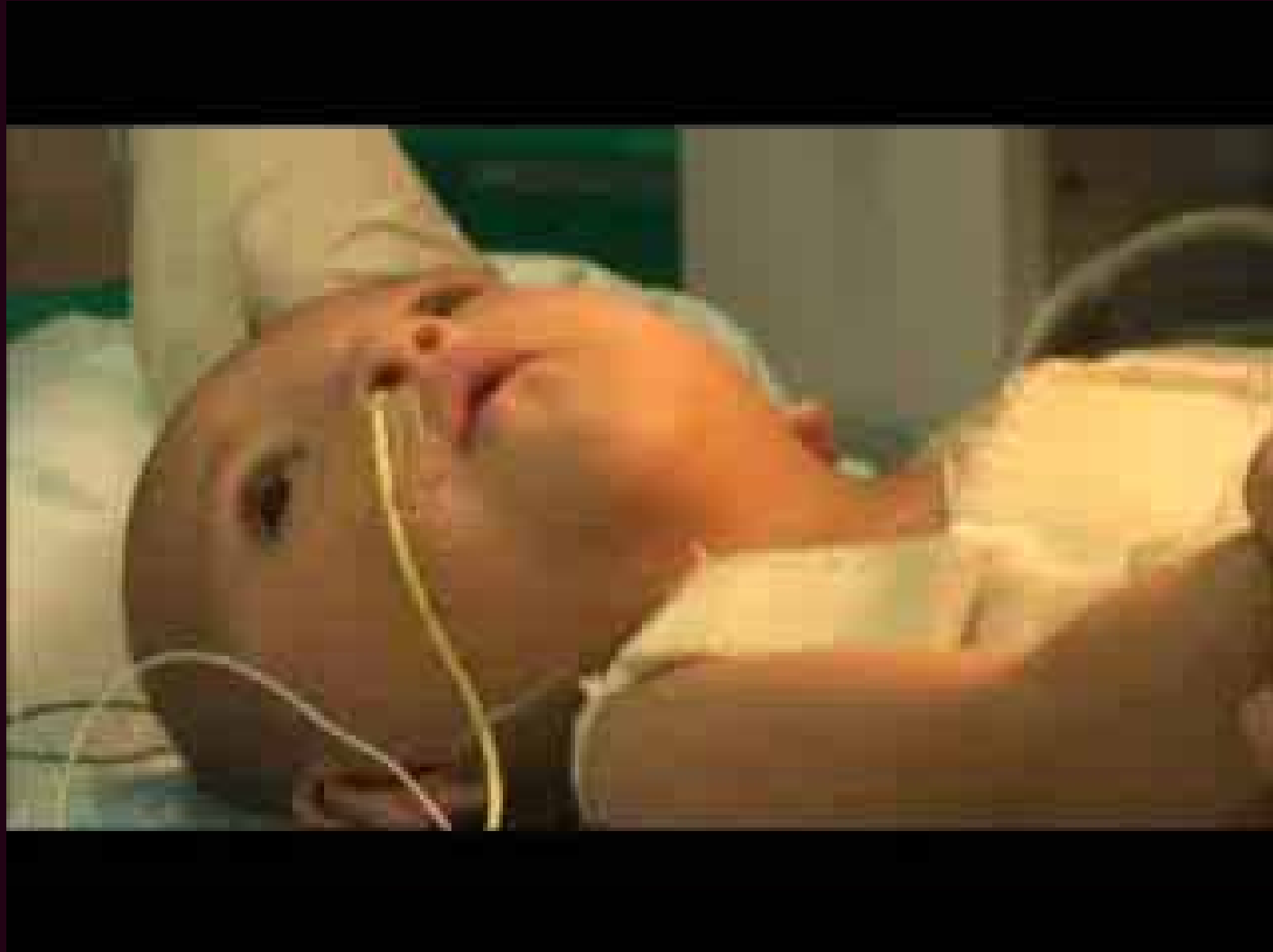- First described by Beattie in '02
(Use for pediatric difficult airway management described by Holm-Knudsen in 2005)
- Provides:
 - Oxygen
 - Anesthesia
 - Time
 - Free hands
 - Orientation



Modified Nasal Trumpet Providing Orientation
during
Nasal FOI in a 2yo with Hemifacial Microsomia



**Modified Nasal Trumpet Providing
Oxygen, Anesthesia, Time, and Free Hands
for Oral FOI in a 5 mo with Cri du Chat**



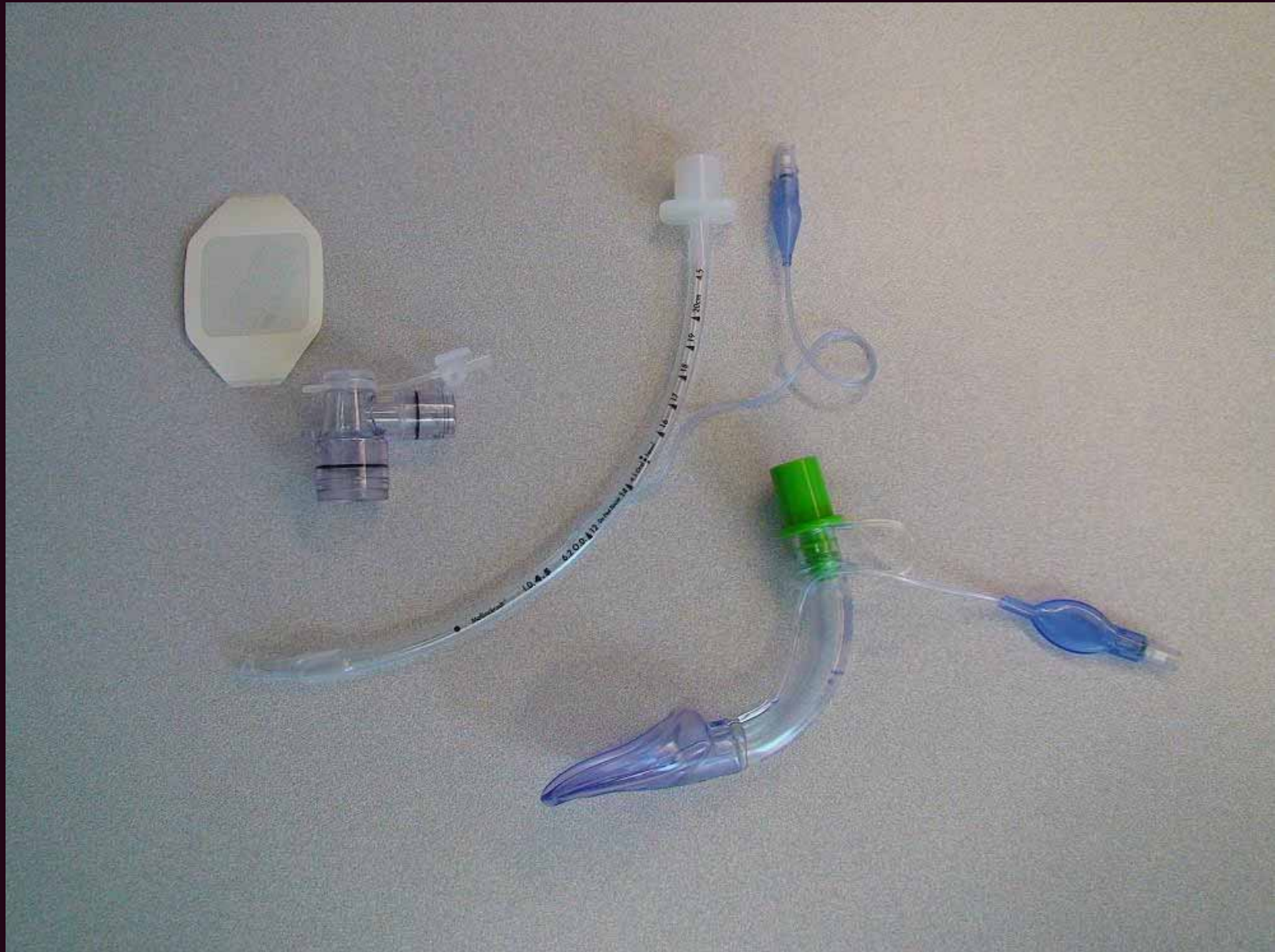
Continuous ventilation during fiberoptic intubation through a laryngeal mask

Variation of technique described by Weiss *et al* in
2004

Provides:

- Oxygen
- Anesthesia
- Time
- Free hands
- Orientation

Equipment Needed



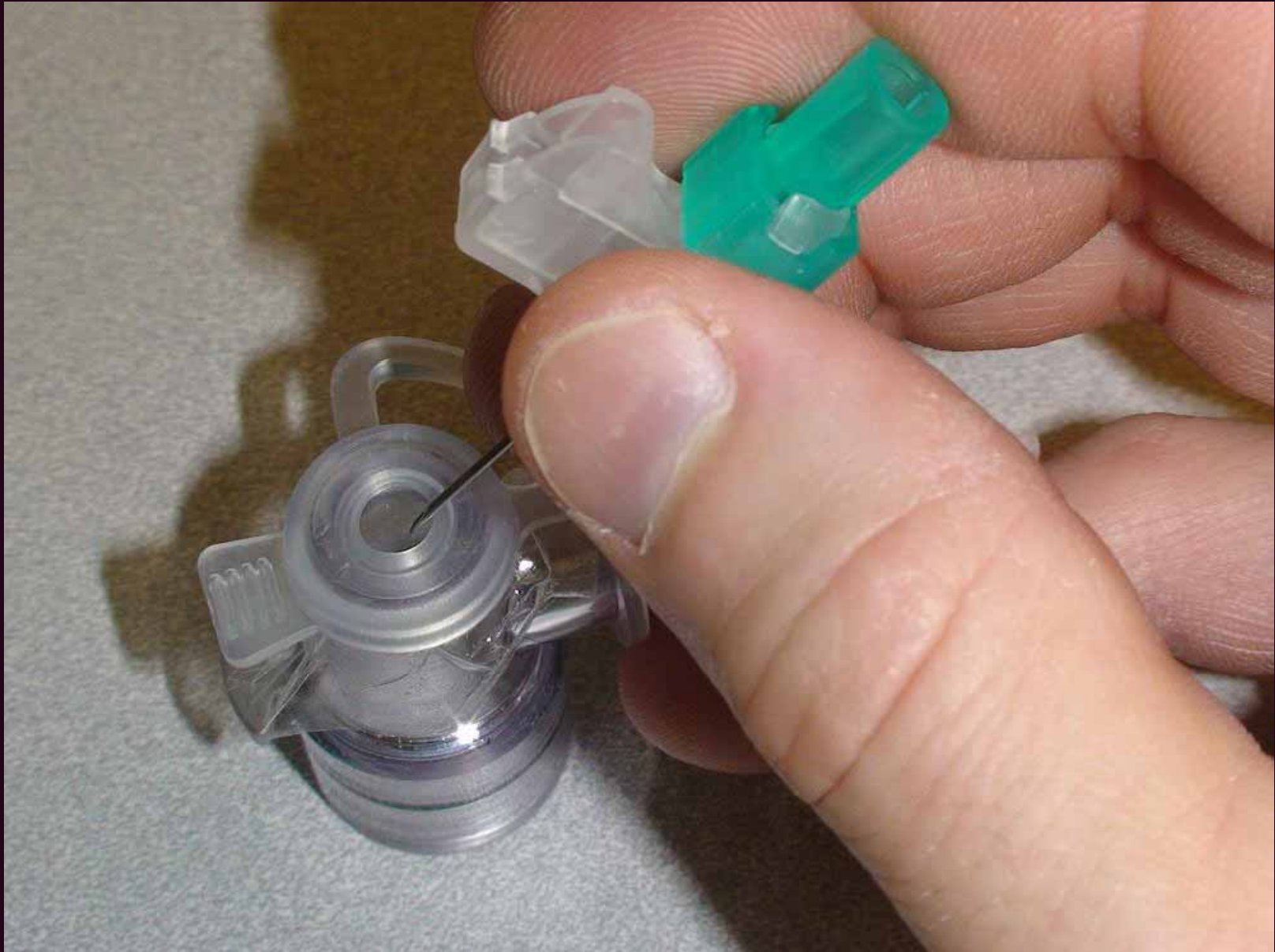
ZEEP keeper



Swivel Adaptor with Tegaderm Diaphragm



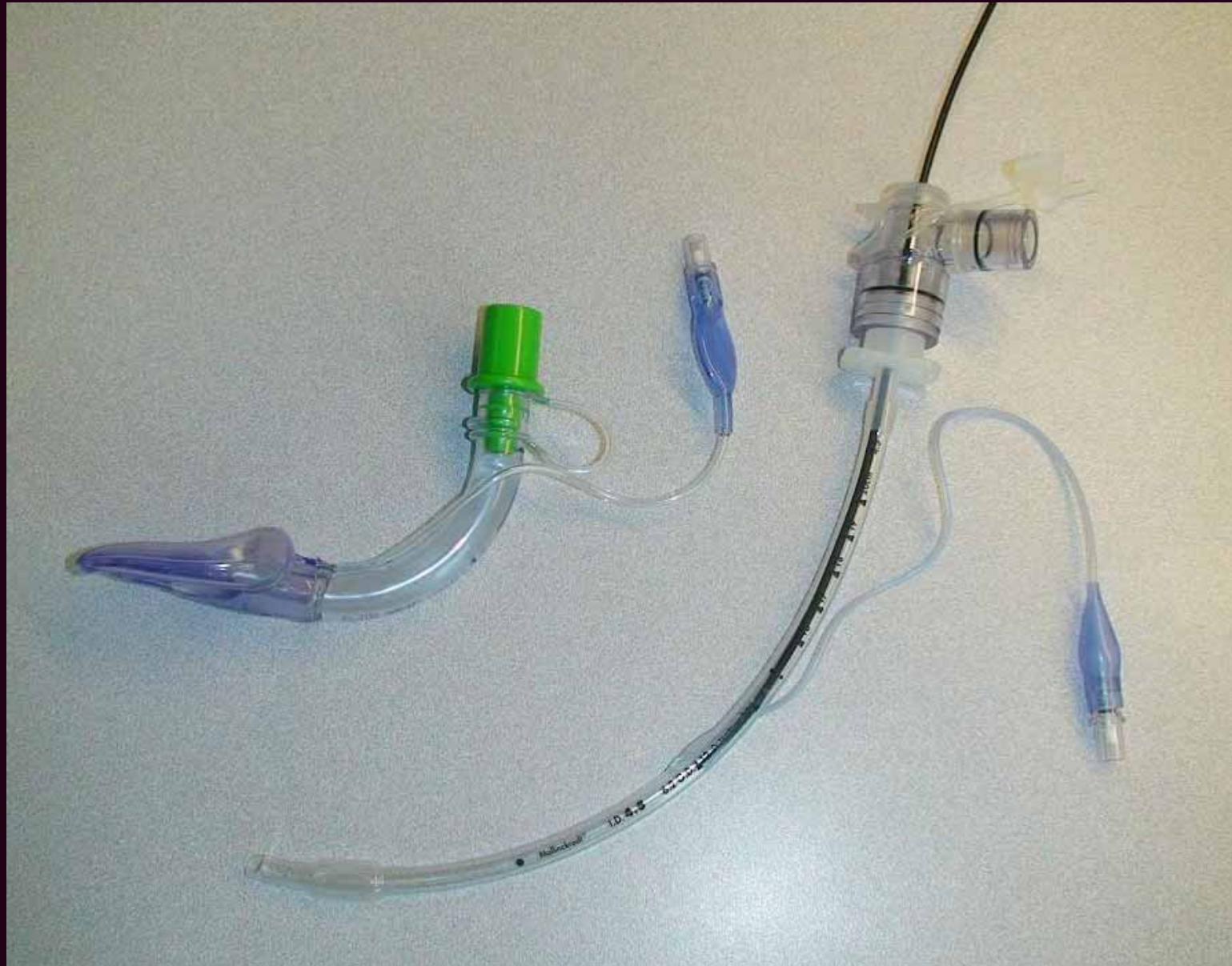
Cut a Small Slit in the Tegaderm



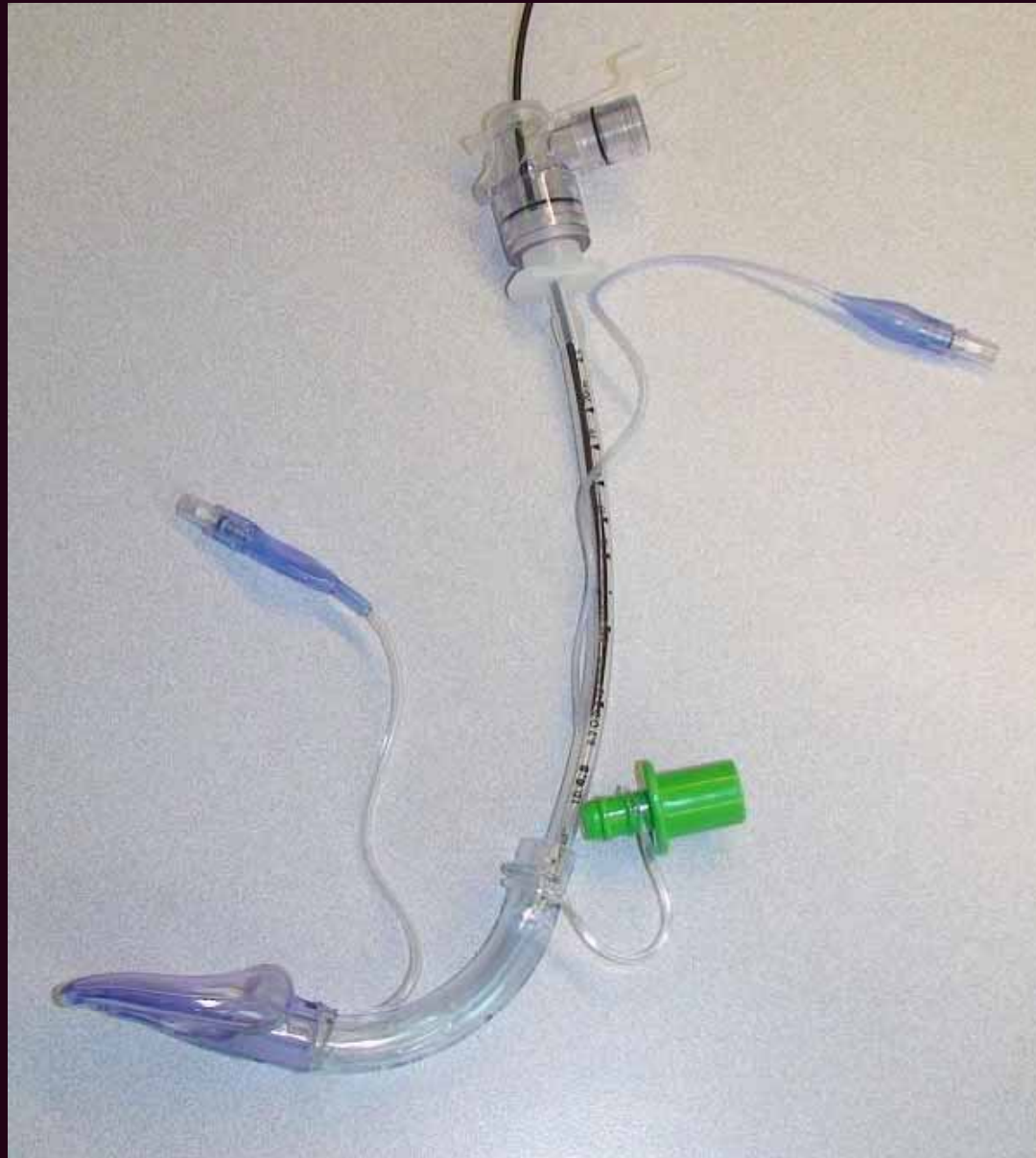
Now it's a PEEP keeper!



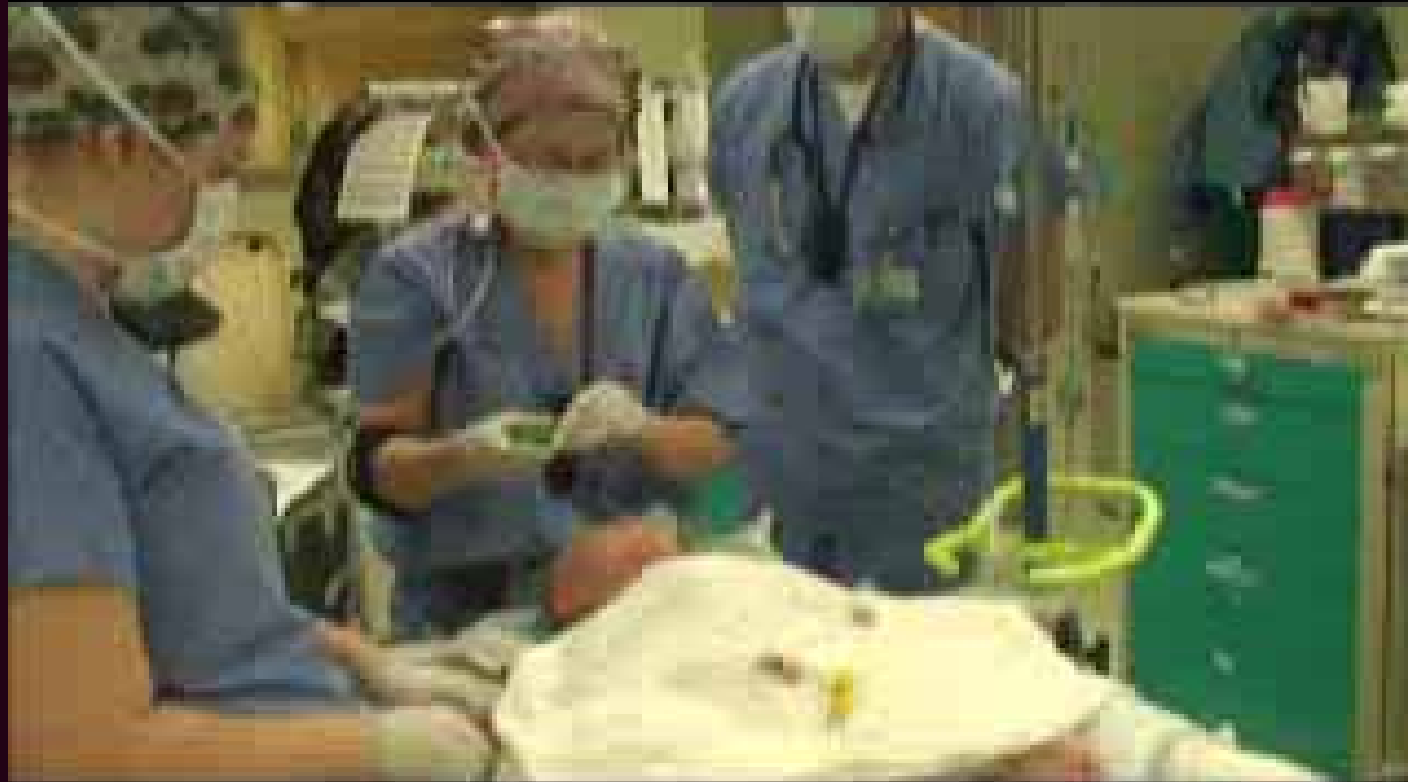Assembly prior to intubation attempt



Assembly during intubation attempt



Continuous Ventilation during Fiberoptic Intubation through a Laryngeal Mask



What is a Difficult Airway?

“The clinical situation in which a conventionally trained anesthesiologist experiences difficulty with face mask ventilation of the upper airway, difficulty with tracheal intubation, or both.”

-Suggested definition from
2003 ASA Practice Guidelines

Summary

- Infants and children present with anatomic, physiologic, and psychological challenges that differ from adults
- There is no one way to manage children with difficult airways
- The flexible bronchoscope remains an indispensable tool
- Other recently introduced tools offer significant advantages in many situations